CARDIOVASCULAR SYSTEM: EARLY DEVELOPMENT - II

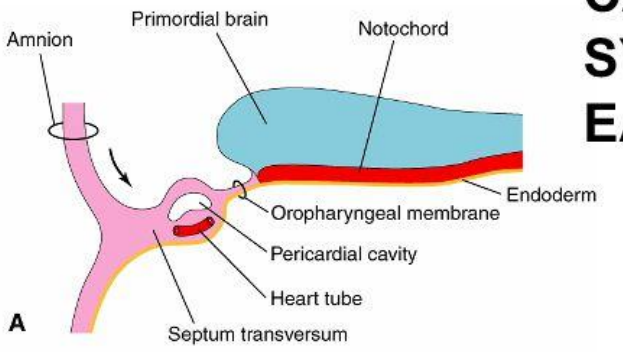

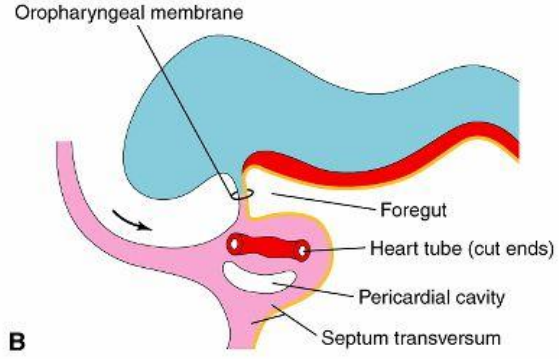

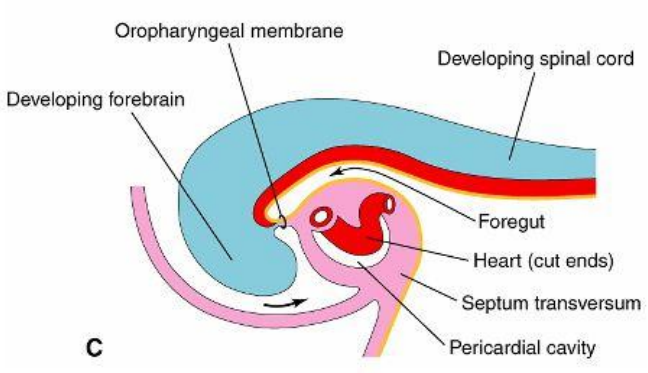

Copyright © 2003, Elsevier Science (USA). All Rights Reserved.

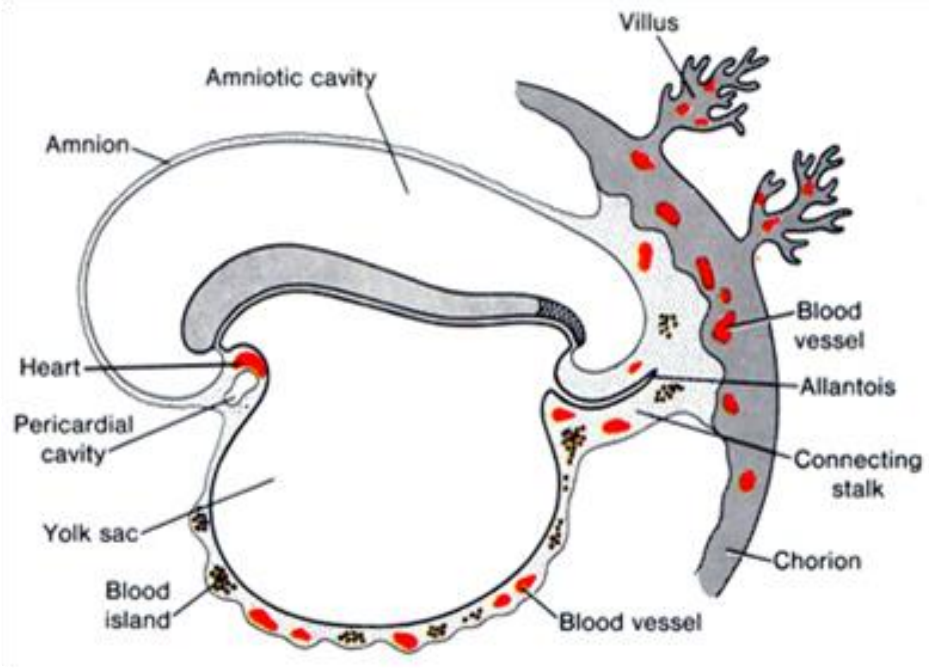

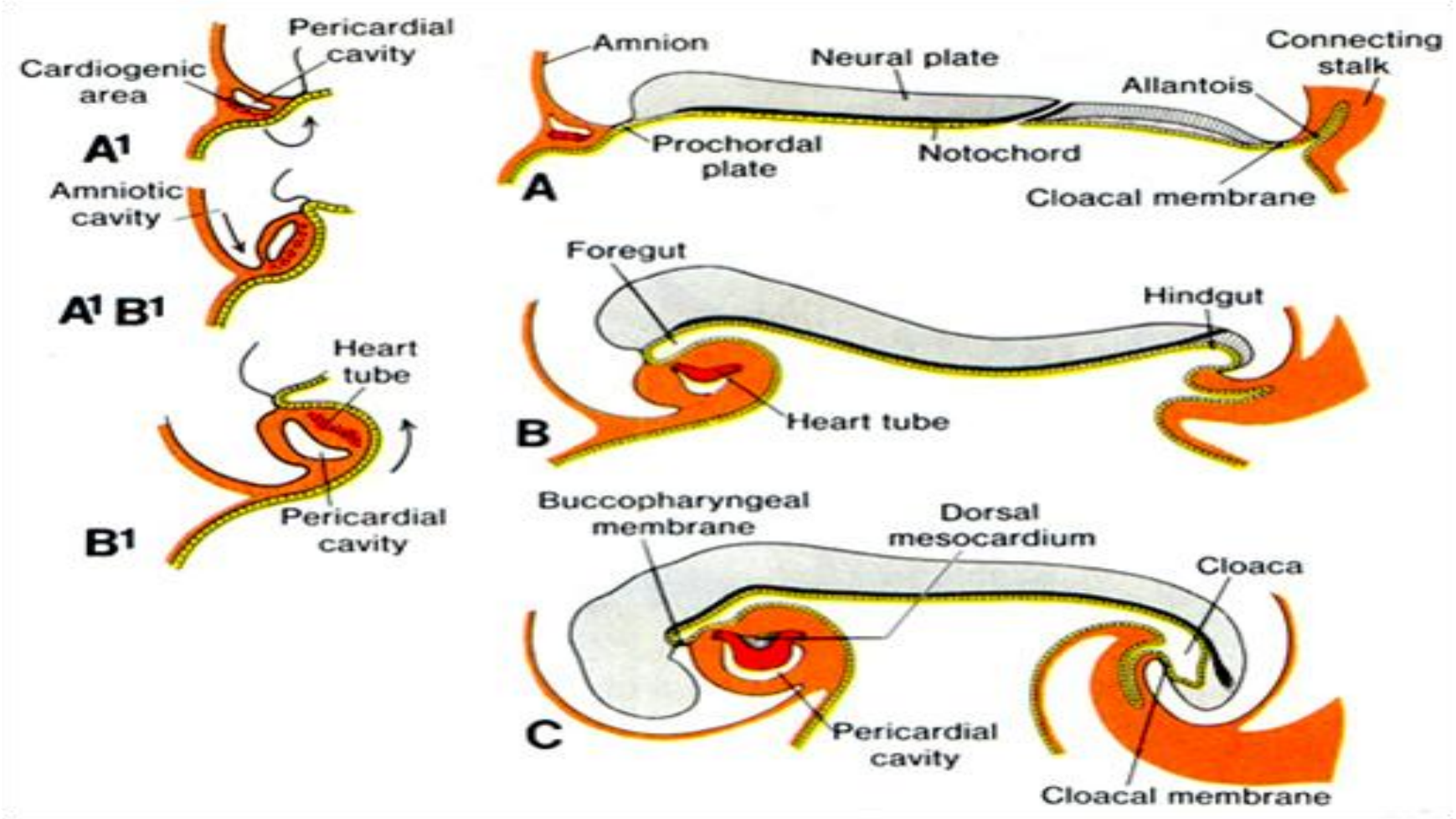
Pericardial cavity
Cardiogenic area
A1
Amniotic cavity
A1 B1
Heart tube
Pericardial cavity
B1
Amnion
Neural plate
Connecting stalk
Allantois
Prochordal plate
Notochord
A
Cloacal membrane
Foregut
Hindgut
Heart tube
B
Buccopharyngeal membrane
Dorsal mesocardium
Cloaca
C
Pericardial cavity
Cloacal membrane

CARDIOVASCULAR SYSTEM: EARLY DEVELOPMENT - I

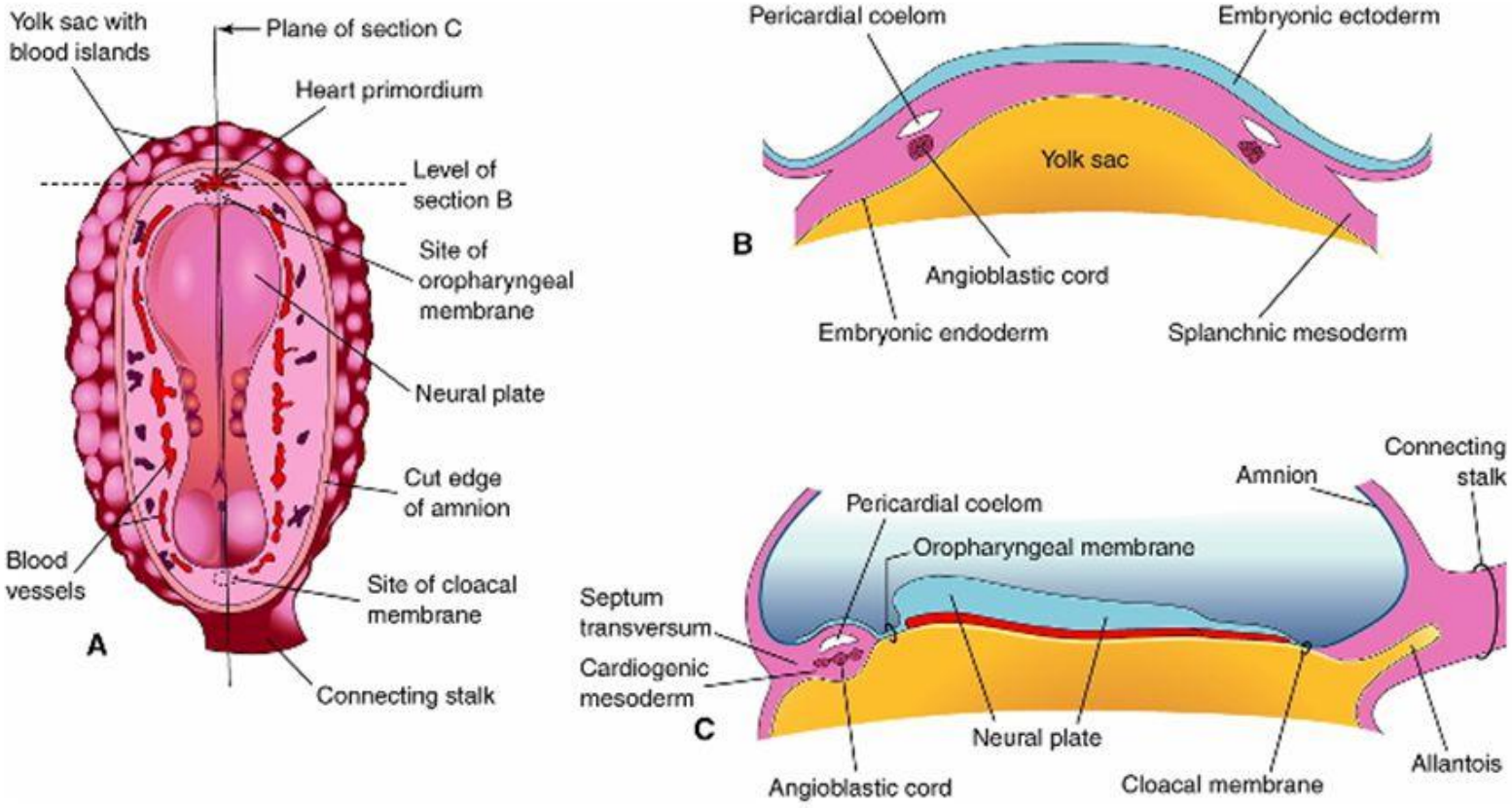

Copyright © 2003, Elsevier Science (USA). All Rights Reserved.

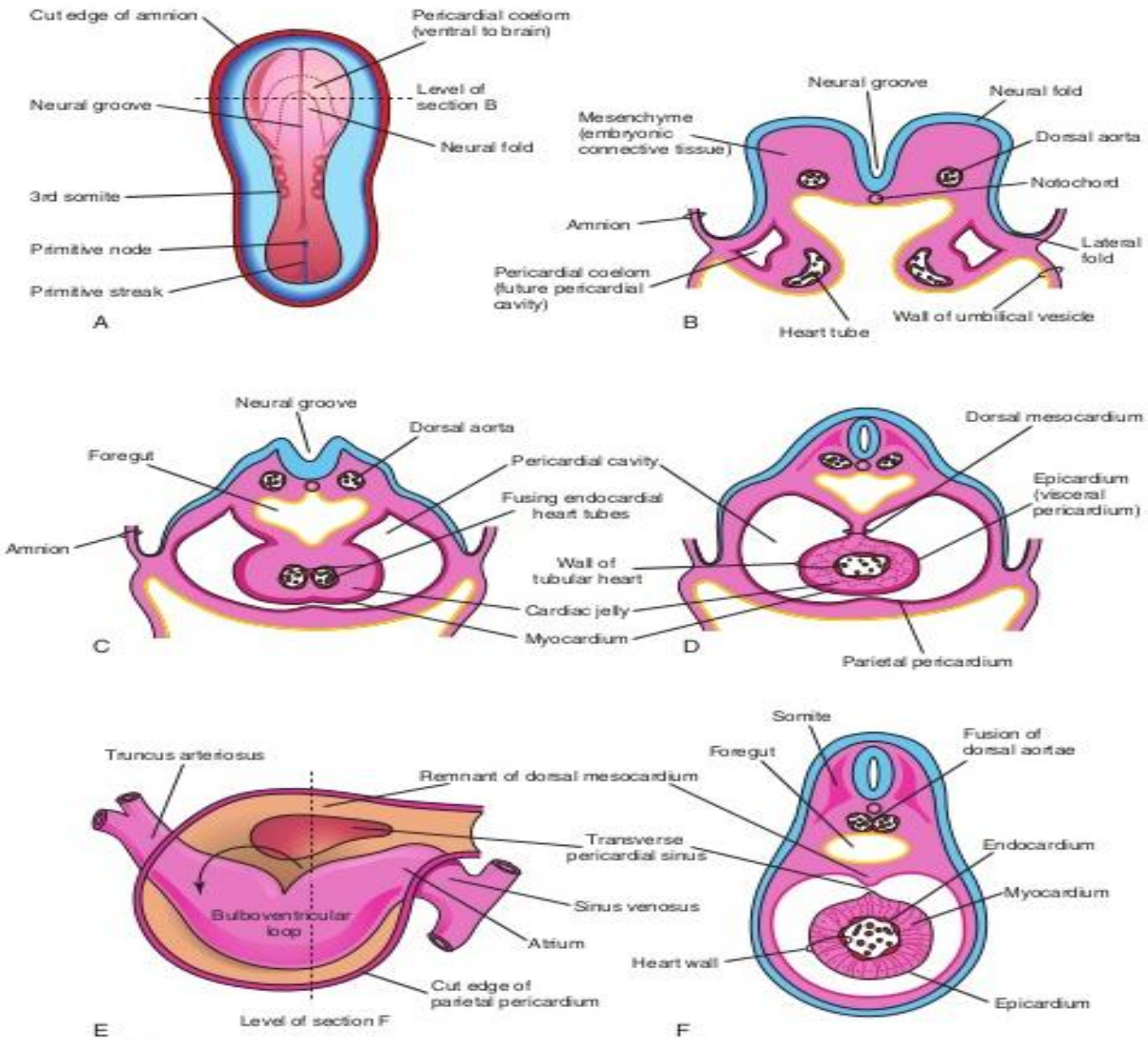
Cut edge of amnion
Pericardial coelom (ventral to brain)
Level of section B
Neural groove
Neural fold
3rd somite
Primitive node
Primitive streak
A
Neural groove
Neural fold
Mesenchyme (embryonic connective tissue)
Dorsal aorta
Notochord
Amnion
Lateral fold
Pericardial coelom (future pericardial cavity)
Heart tube
Wall of umbilical vesicle
B
Neural groove
Dorsal aorta
Foregut
Pericardial cavity
Fusing endocardial heart tubes
Amnion
Wall of tubular heart
Cardiac jelly
Myocardium
C
Dorsal mesocardium
Epicardium (visceral pericardium)
Parietal pericardium
D
Truncus arteriosus
Remnant of dorsal mesocardium
Transverse pericardial sinus
Sinus venosus
Bulboventricular loop
Atrium
Cut edge of parietal pericardium
Level of section F
E
Somite
Foregut
Fusion of dorsal aortae
Endocardium
Myocardium
Heart wall
Epicardium
F

Formation of a single heart tube

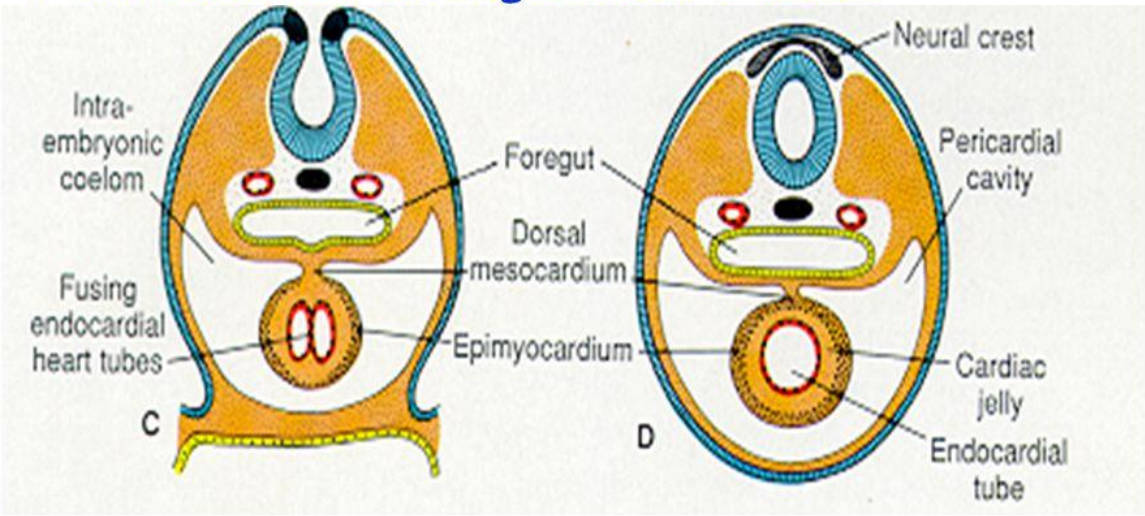

21 days (at 4 somites)
- Fusion of endocardial tubes

22 days (at 8 somites)
- Single endocardial tube

Heart tubes

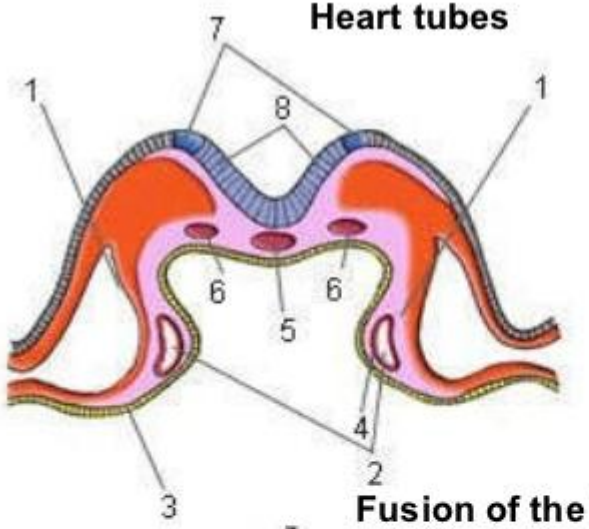

1. Epimyocardial cells
2. Heart tube
3. Endoderm
4. Endocardial cells
5. Notochord
6. Dorsal aorta
7. Neural crest
8. Neural fold

Fusion of the heart tubes

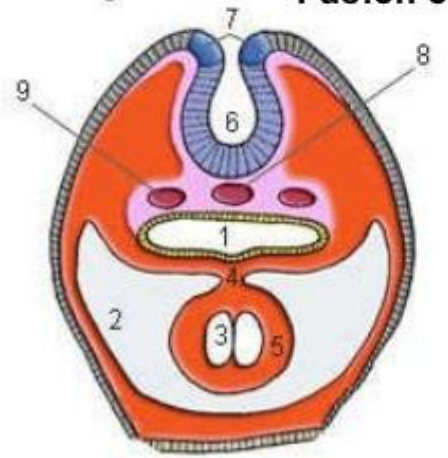

1. Foregut
2. Intraembryonic coelom
3. Heart tubes
4. Dorsal mesocardium
5. Epimyocardium
6. Neural groove
7. Neural crest
8. Notochord
9. Dorsal aorta

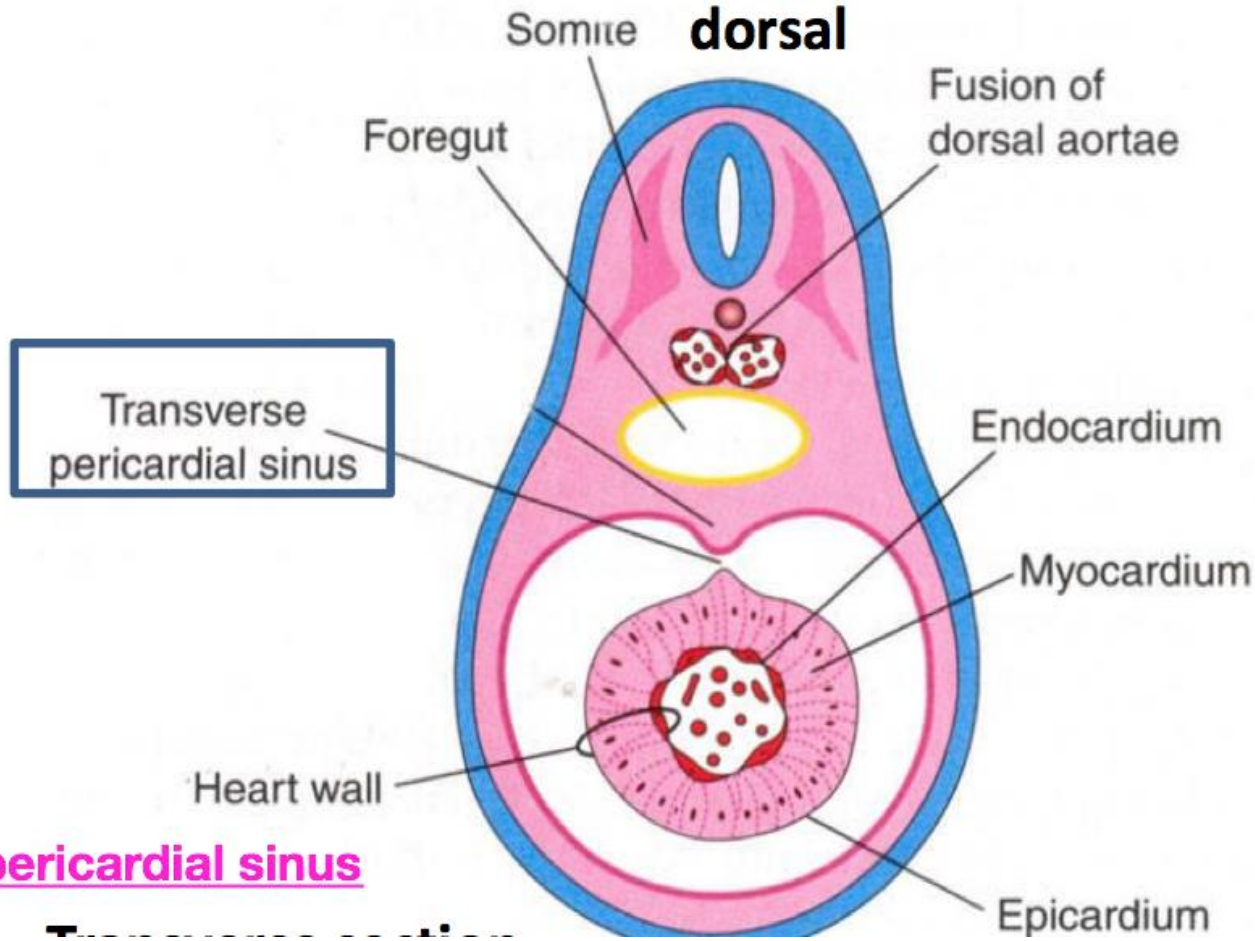

e pericardial sinus

Formation of Cardiac loop

Normal D-looping

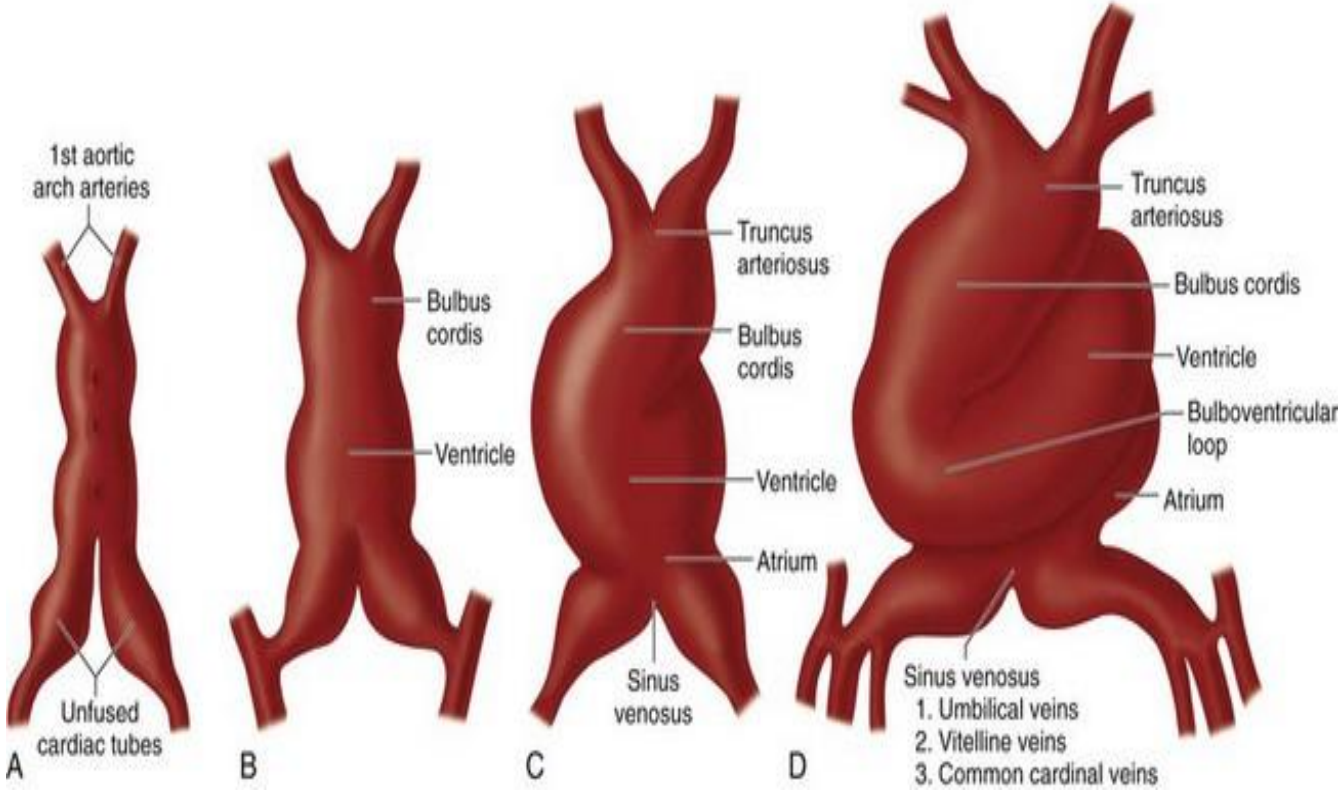

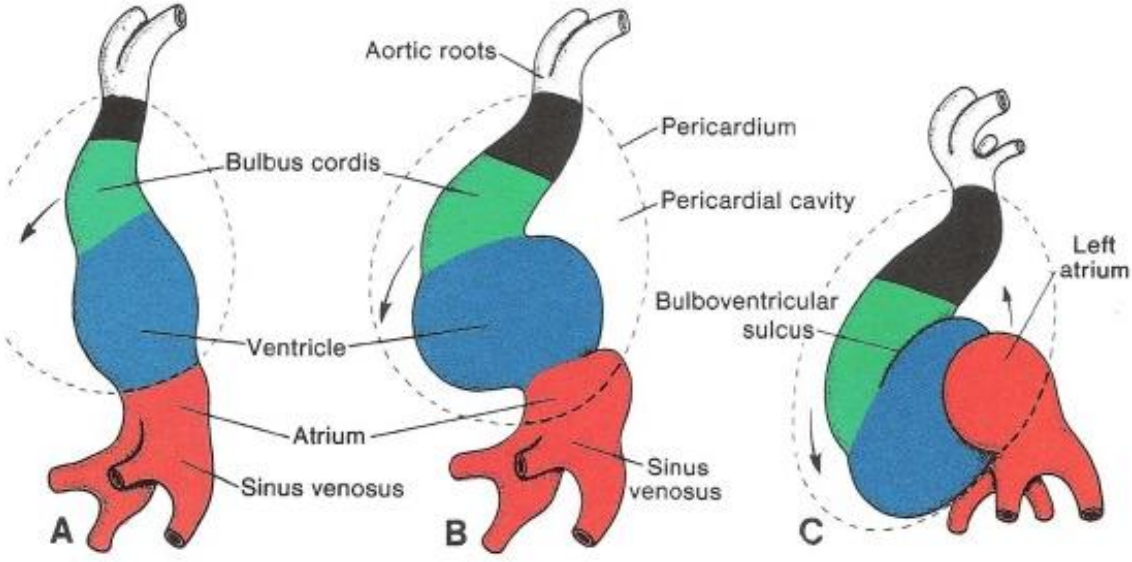

A, day 22 *B*, day 23 *C*, day 24

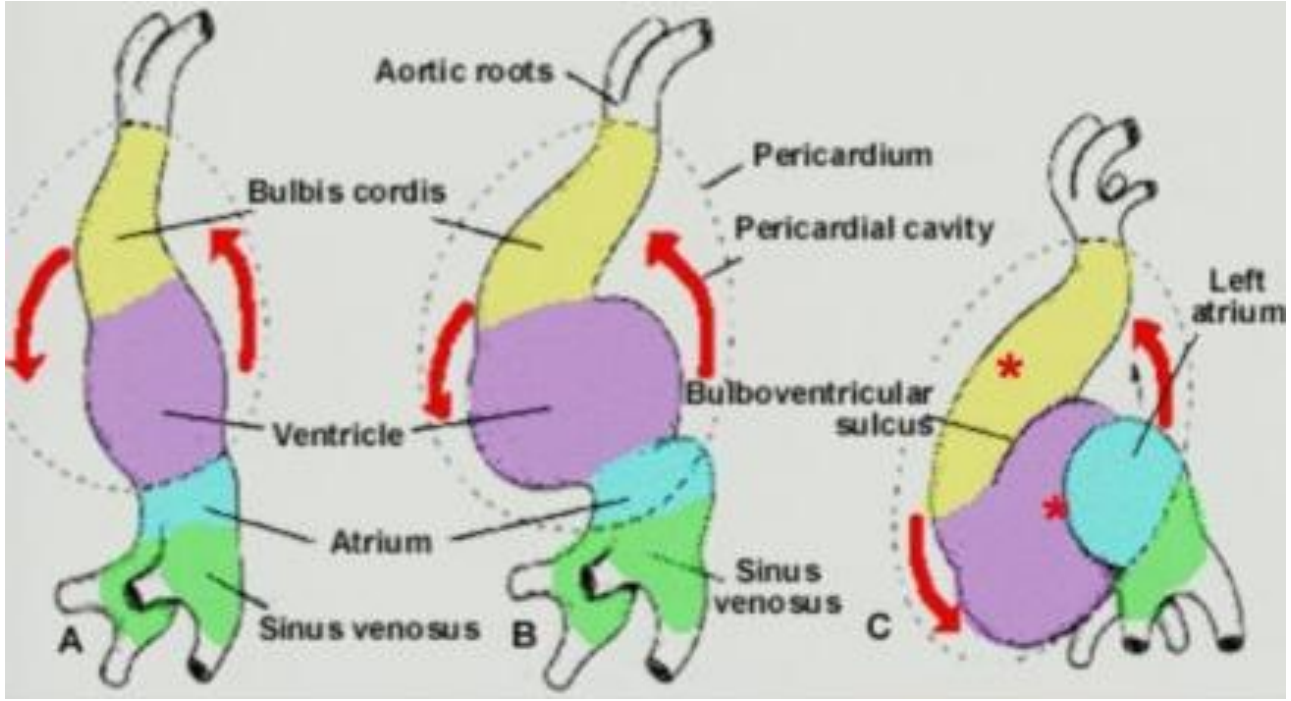
Aortic roots
Pericardium
Bulbis cordis
Pericardial cavity
Left atrium
Bulboventricular sulcus
Ventricle
Atrium
Sinus venosus
Sinus venosus
A
B
C

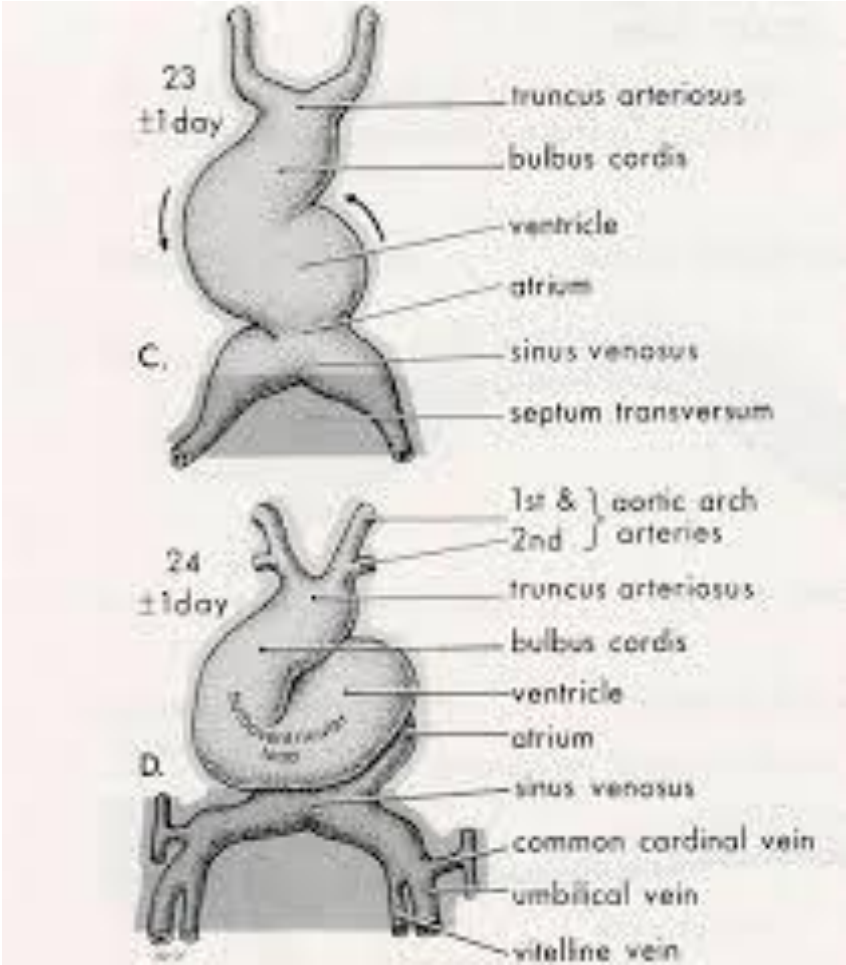
23 ±1day
truncus arteriosus
bulbus cordis
ventricle
atrium
sinus venosus
septum transversum
C.
1st & 2nd
aortic arch arteries
24 ±1day
truncus arteriosus
bulbus cordis
ventricle
atrium
sinus venosus
common cardinal vein
umbilical vein
vitelline vein
D.

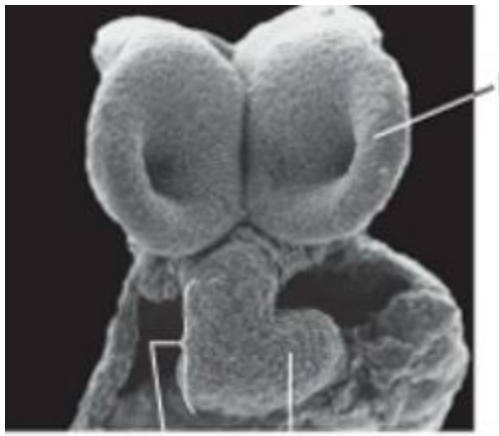

22 days

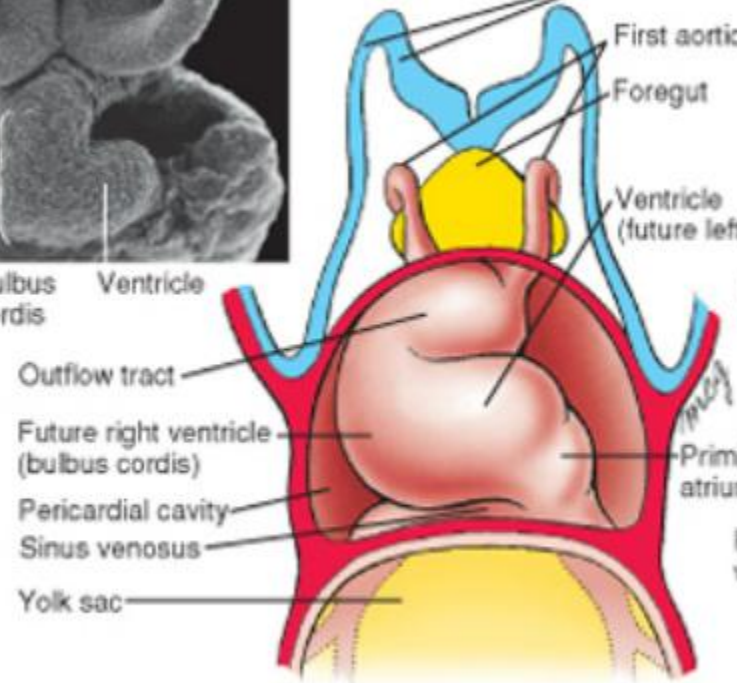

24 days

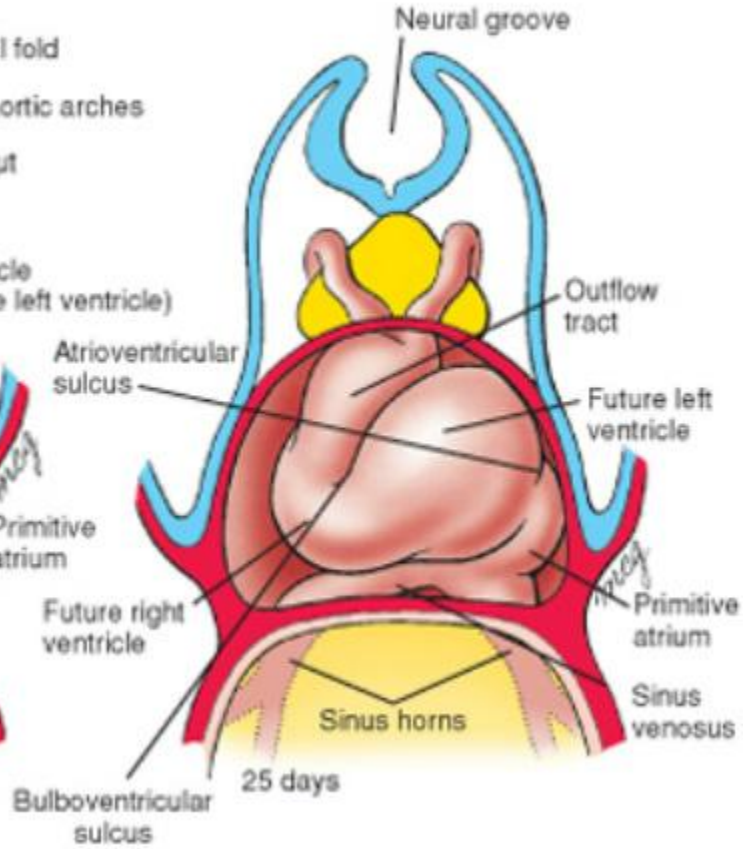

25 days

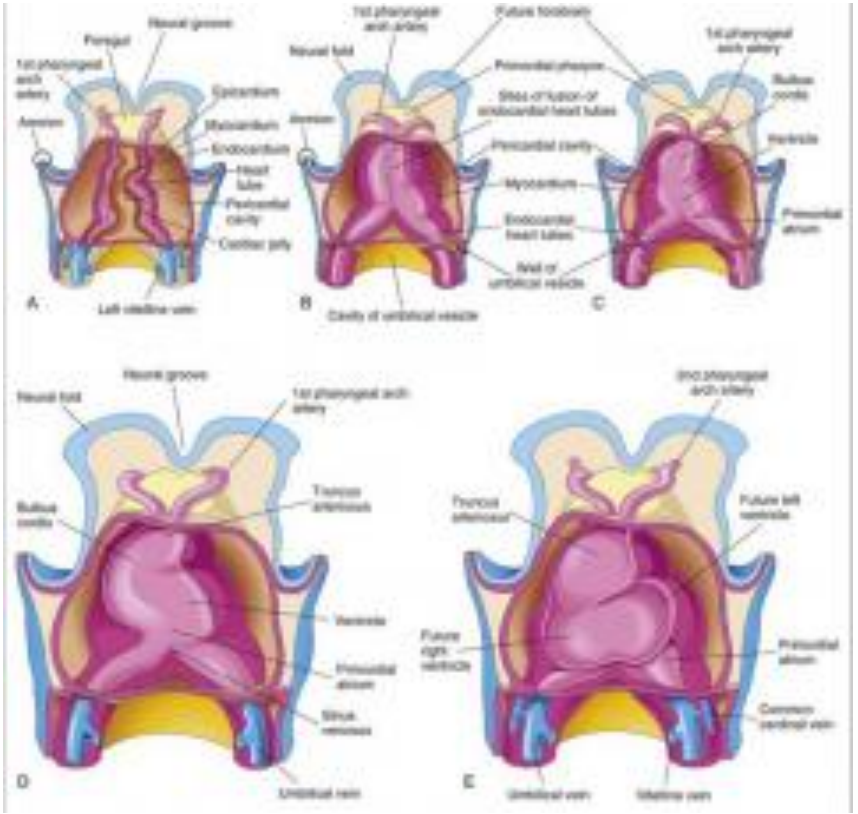

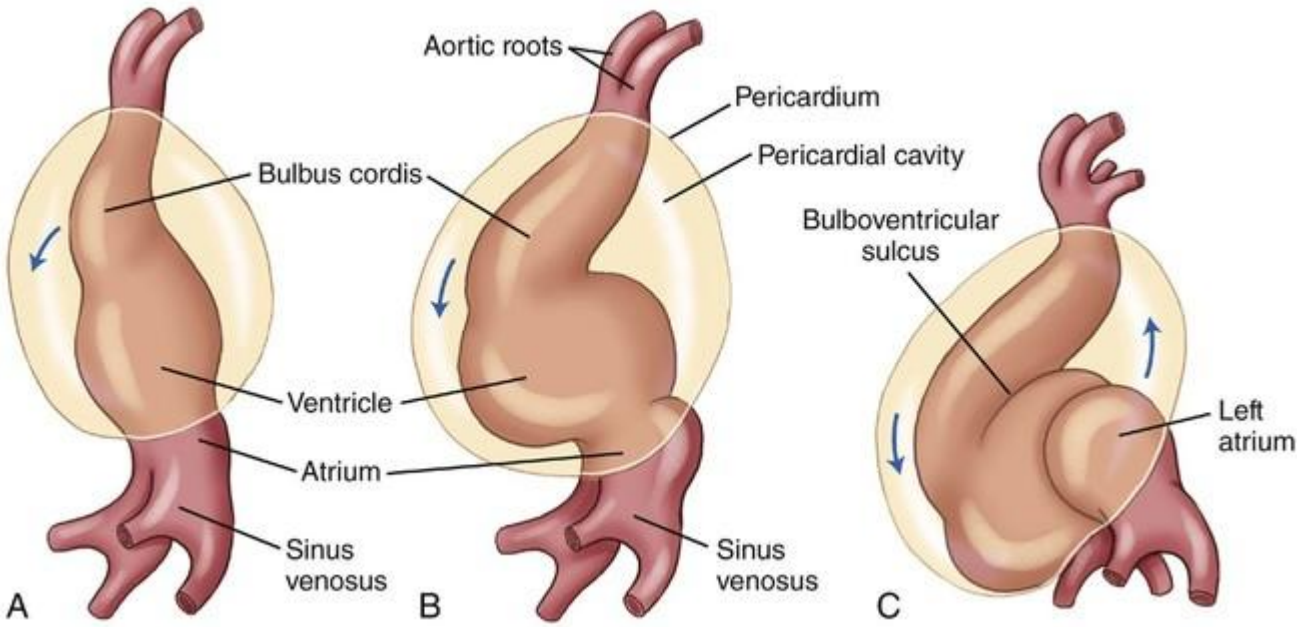

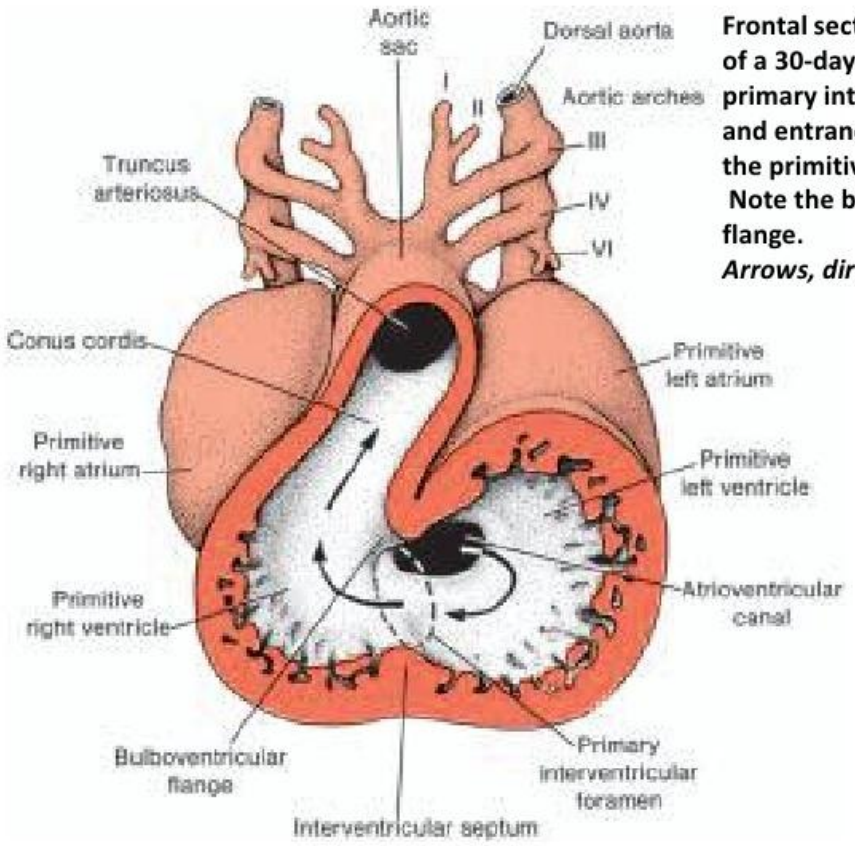

Frontal section through the heart of a 30-day embryo showing the primary interventricular foramen and entrance of the atrium into the primitive left ventricle.
Note the bulboventricular flange.
Arrows, direction of blood flow.

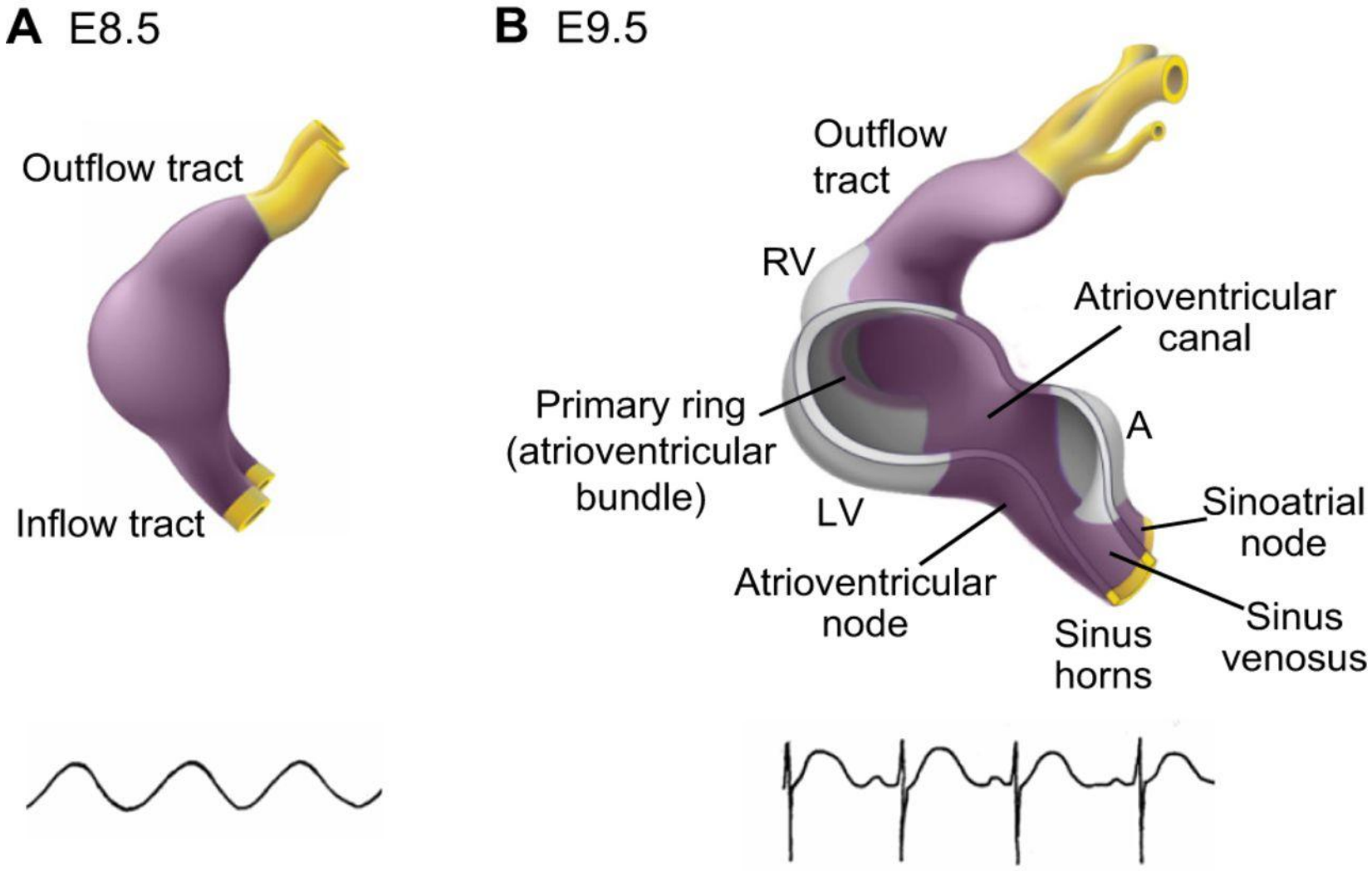
A E8.5
Outflow tract
Inflow tract
B E9.5
Outflow tract
RV
Atrioventricular canal
Primary ring (atrioventricular bundle)
A
LV
Sinoatrial node
Atrioventricular node
Sinus horns
Sinus venosus

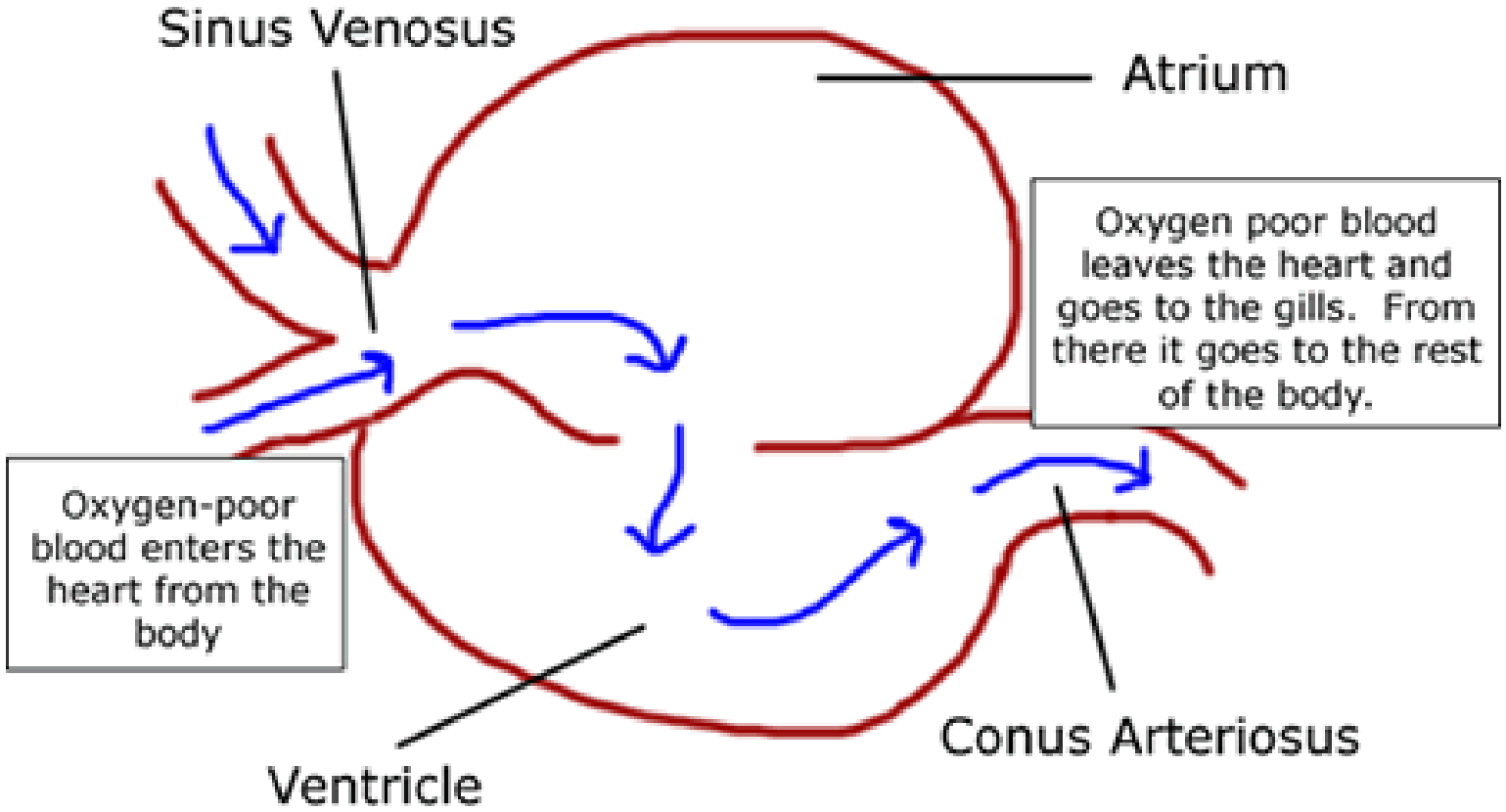
Sinus Venosus
Atrium
Oxygen poor blood leaves the heart and goes to the gills. From there it goes to the rest of the body.
Oxygen-poor blood enters the heart from the body
Ventricle
Conus Arteriosus

تحجب القناة الاذينية البطينية

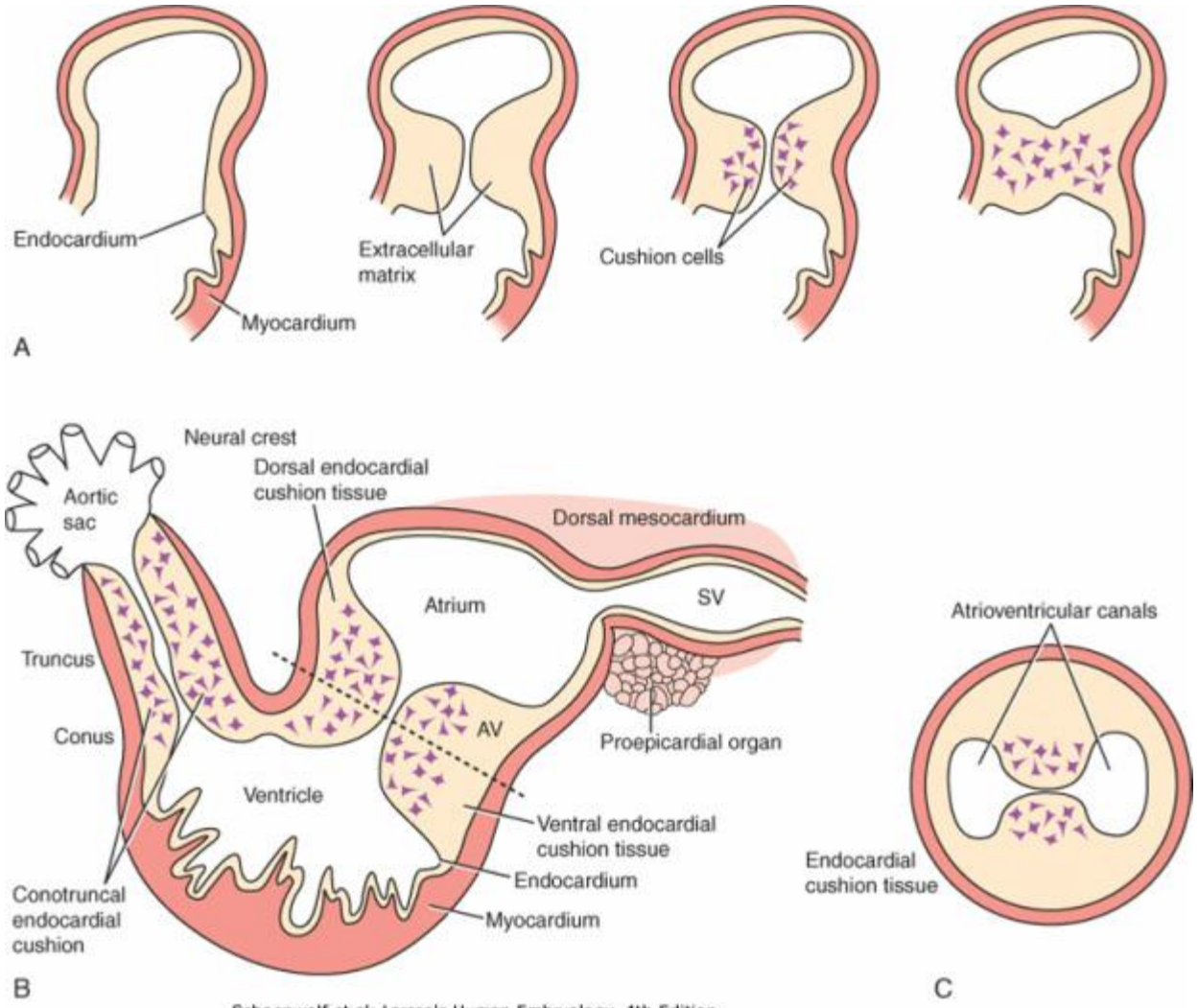

Schoenwolf et al: Larsen's Human Embryology, 4th Edition.
Copyright © 2008 by Churchill Livingstone, an imprint of Elsevier, Inc. All rights reserved

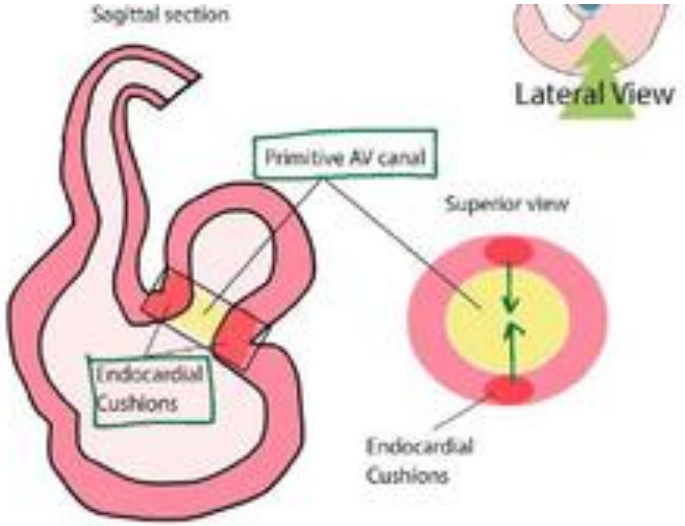

Medial cross-section of the developing heart – Early Week 5

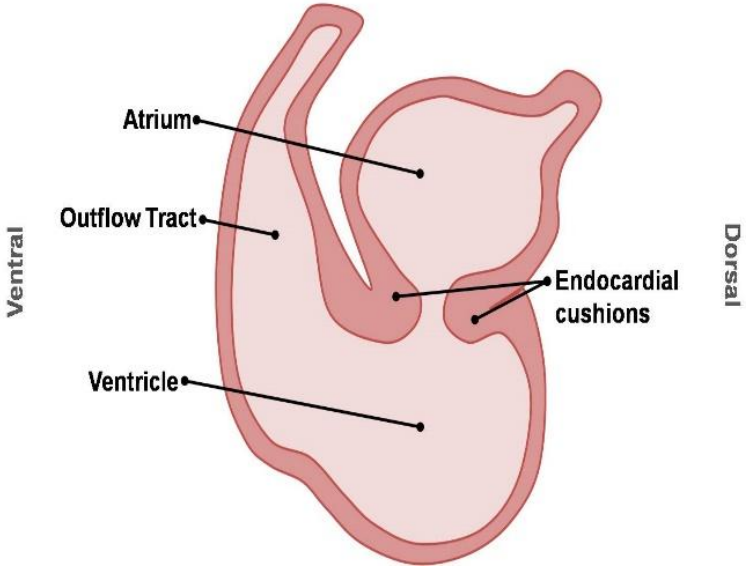

تحجب الاذينة الابتدائية

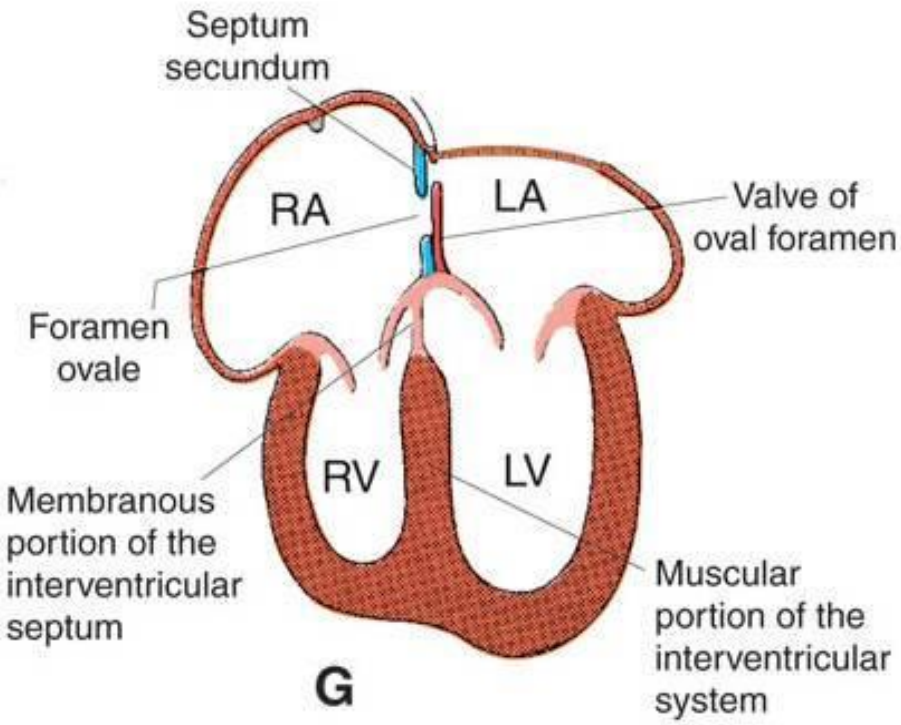

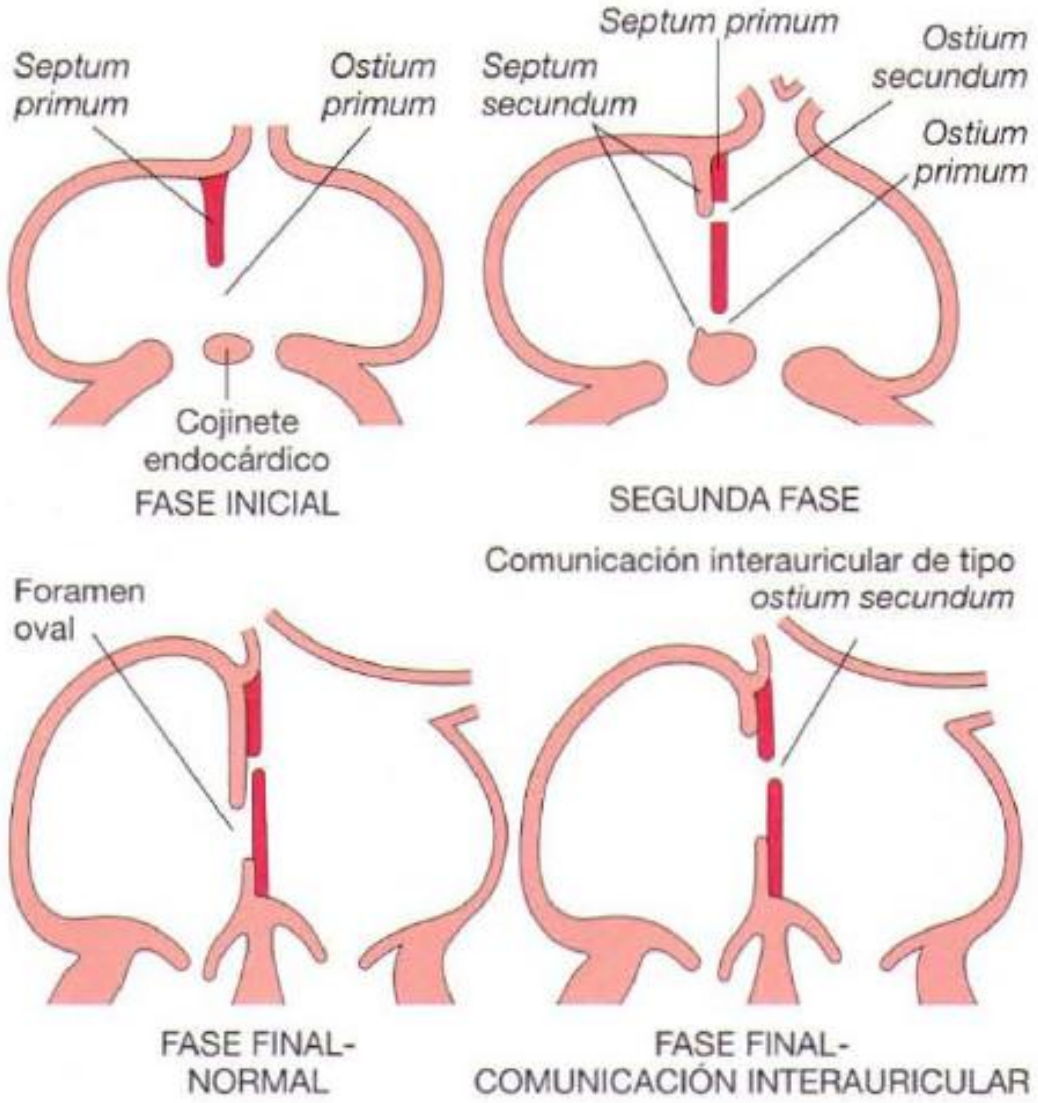

Figura 11-2

Embriogenia de una comunicación interauricular de tipo *ostium secundum*. La aurícula derecha está a la izquierda del *septum primum*.

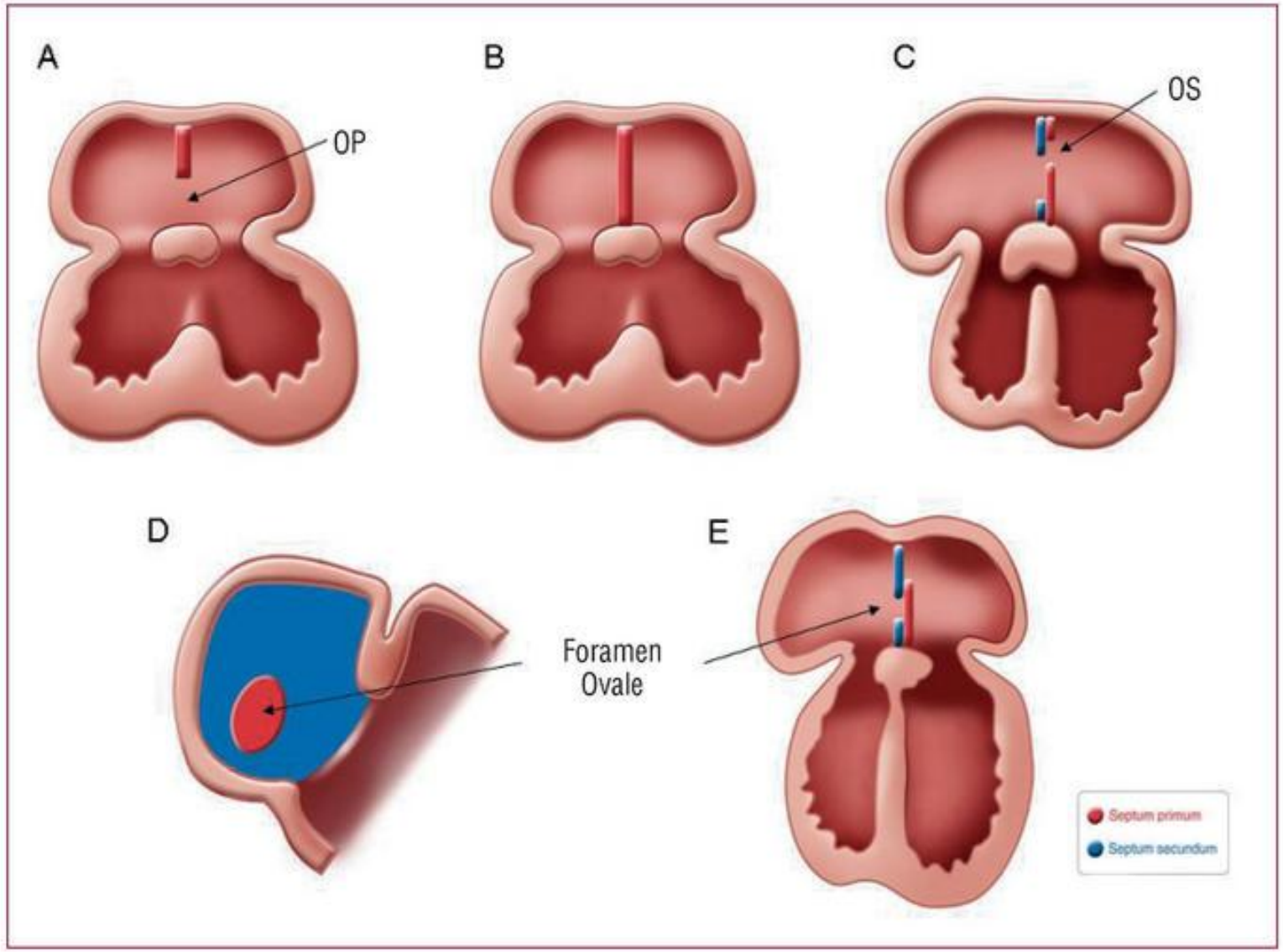
A
OP
B
C
OS
D
Foramen
Ovale
E
Septum primum
Septum secundum

Fate of Sinus Venosus

- The **right horn** forms the smooth posterior wall of the right atrium.
- The **left horn and body** atrophy and form the **coronary sinus.**
- **The left common cardinal vein forms the oblique vein of the left atrium.**

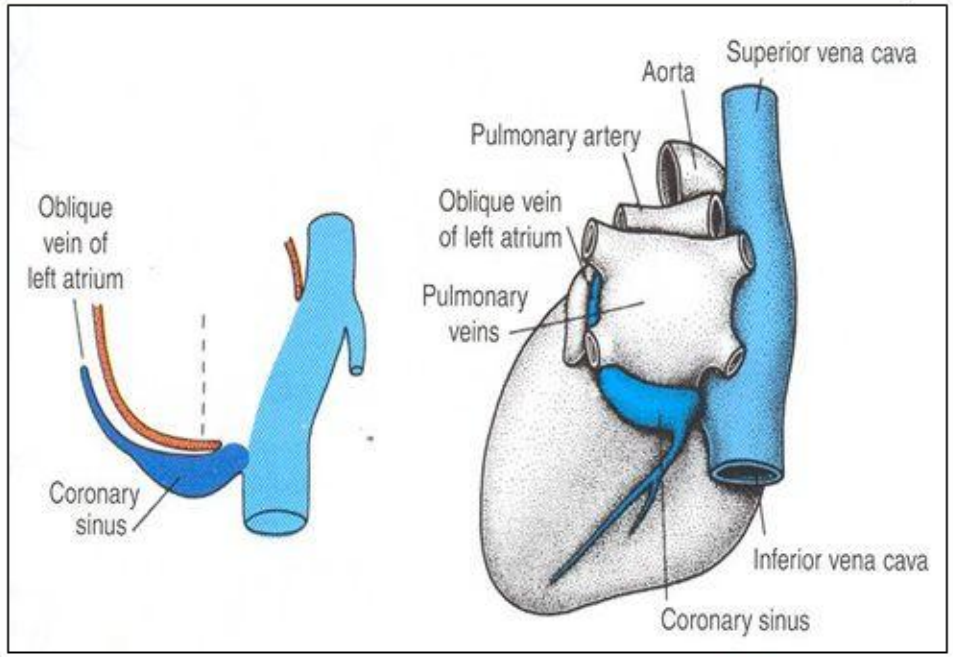

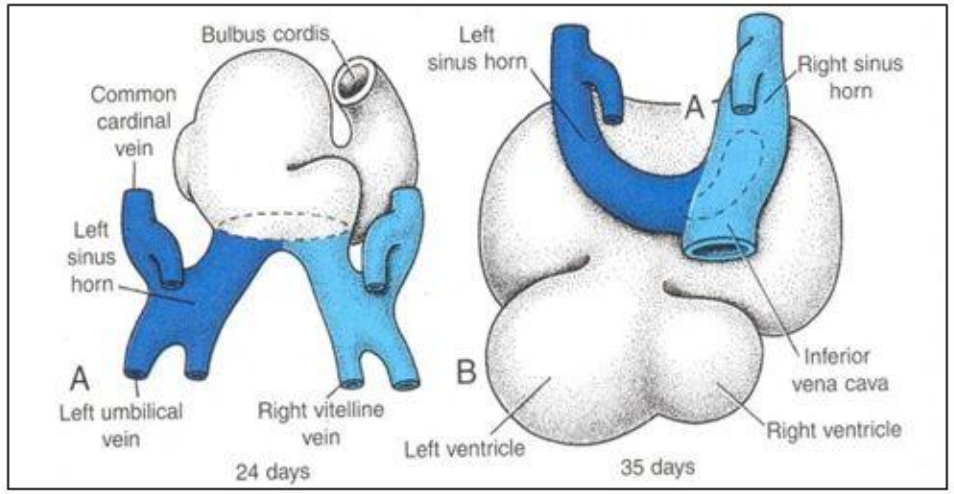

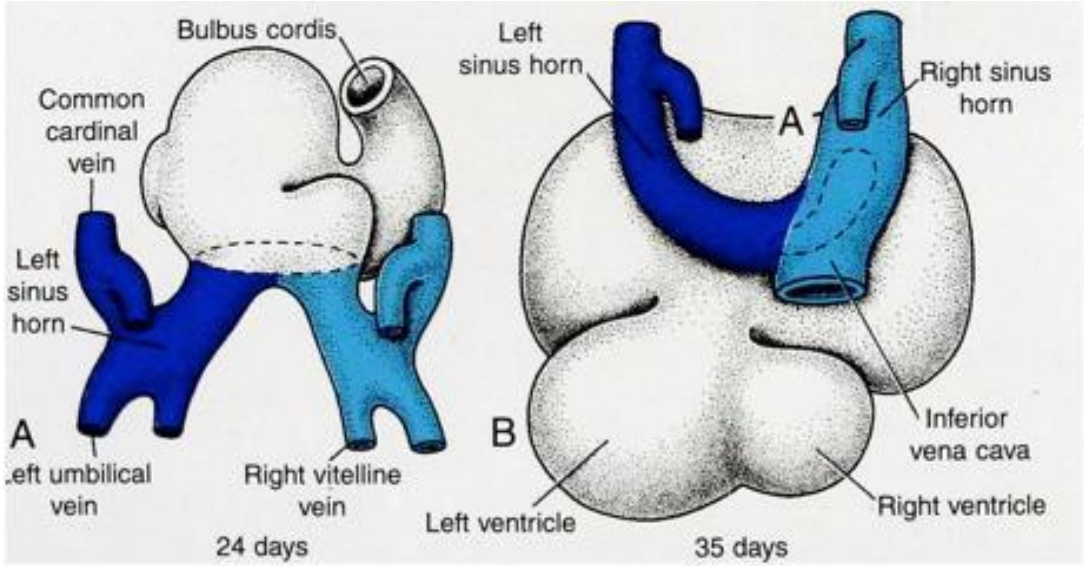
Bulbus cordis
Common cardinal vein
Left sinus horn
A
Left umbilical vein
Right vitelline vein
24 days
Left sinus horn
A
Right sinus horn
B
Inferior vena cava
Left ventricle
Right ventricle
35 days

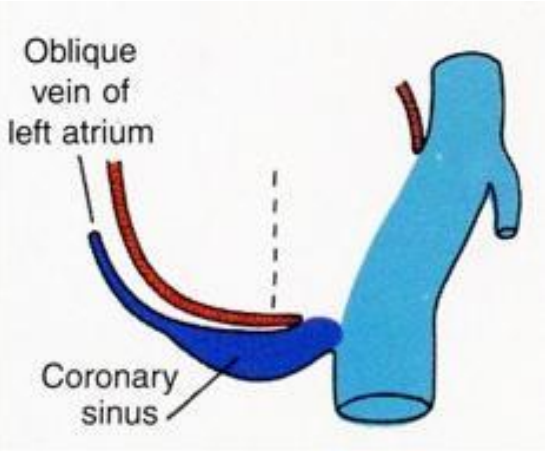
Oblique vein of left atrium
Coronary sinus

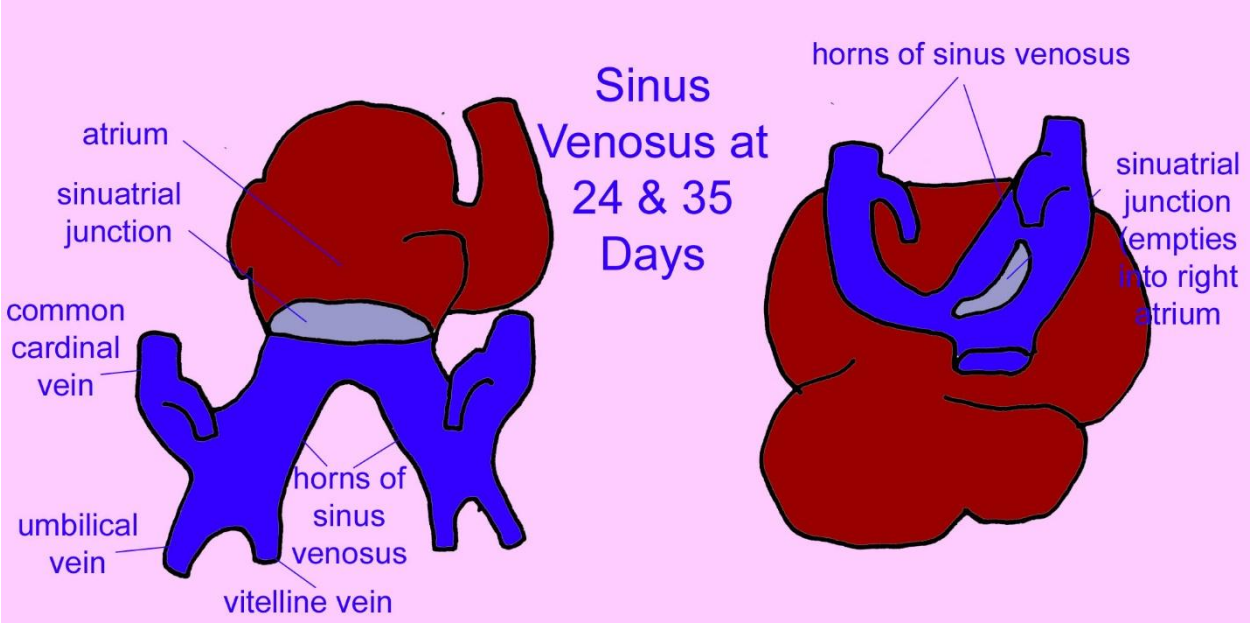
Sinus Venosus at 24 & 35 Days
atrium
sinuatrial junction
common cardinal vein
umbilical vein
horns of sinus venosus
vitelline vein
horns of sinus venosus
sinuatrial junction
(empties into right atrium

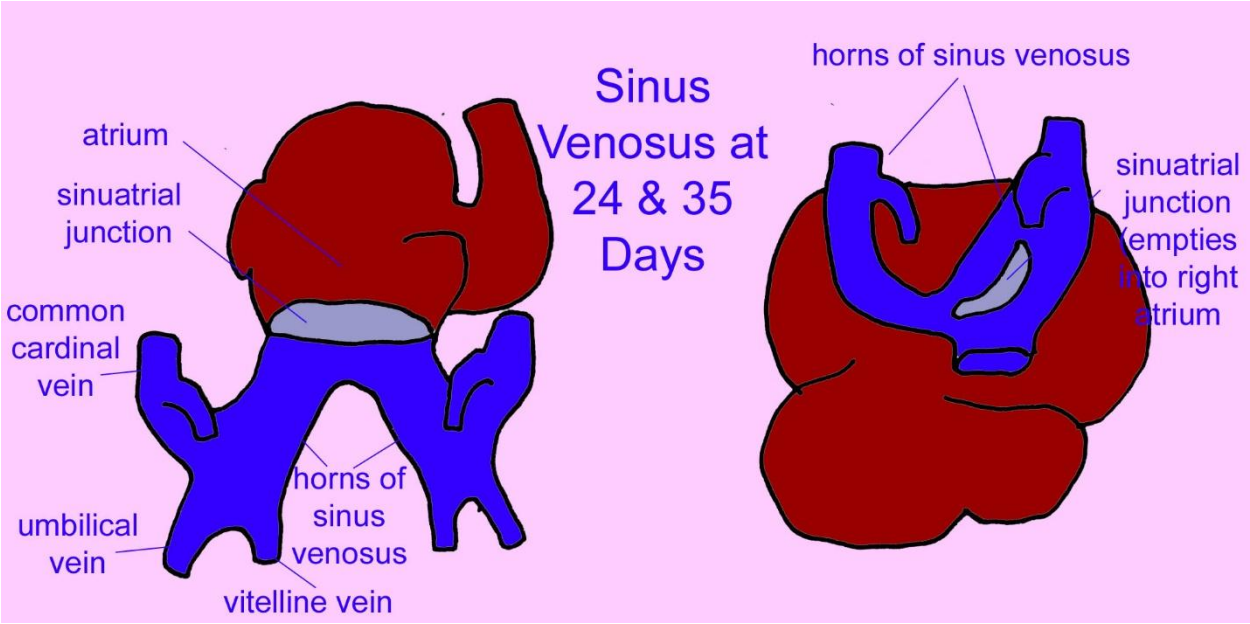

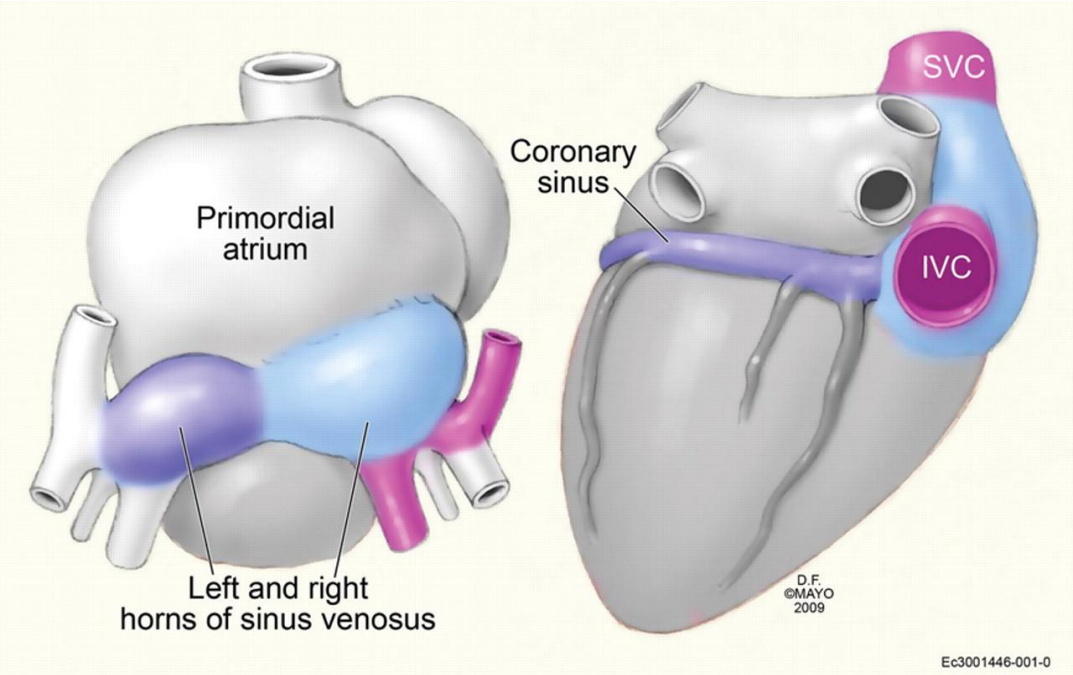

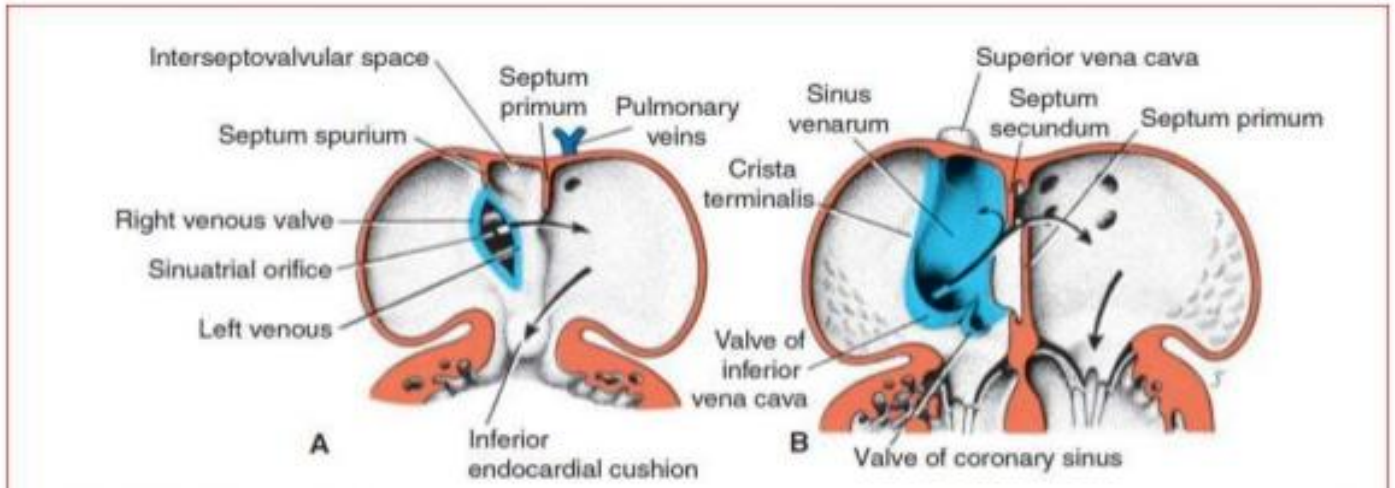

Figure 13.14 Ventral view of coronal sections through the heart at the level of the atrioventricular canal to show development of the venous valves. **A.** 5 weeks. **B.** Fetal stage. The sinus venarum (*blue*) is smooth walled; it derives from the right sinus horn. *Arrows*, blood flow.

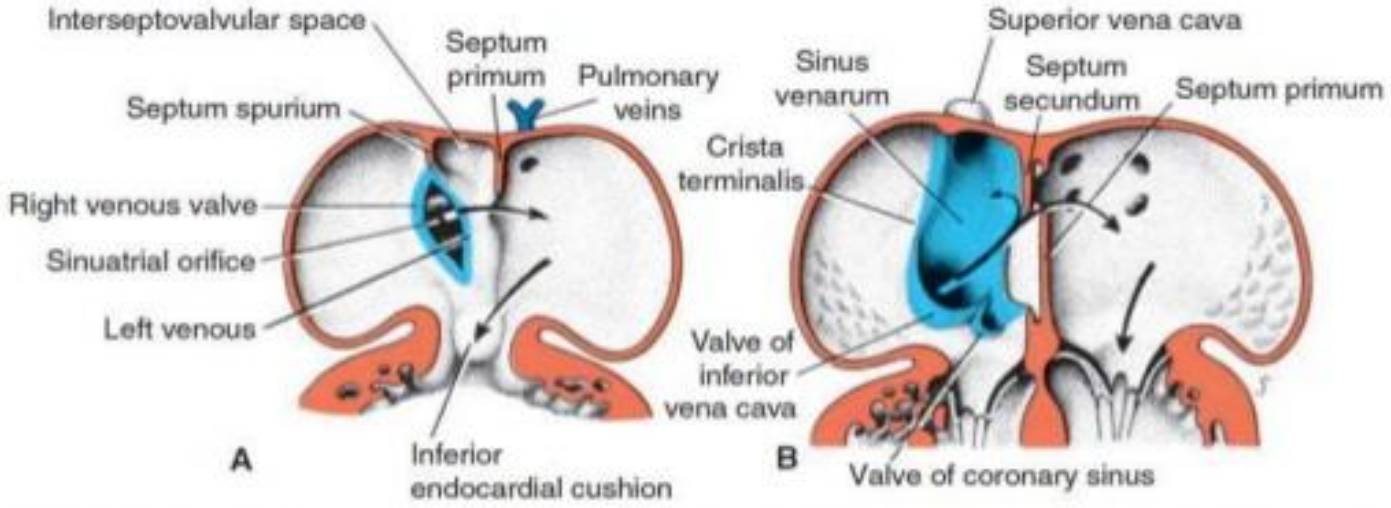

Figure 13.14 Ventral view of coronal sections through the heart at the level of the atrioventricular canal to show development of the venous valves. **A.** 5 weeks. **B.** Fetal stage. The sinus venarum (*blue*) is smooth walled; it derives from the right sinus horn. *Arrows*, blood flow.

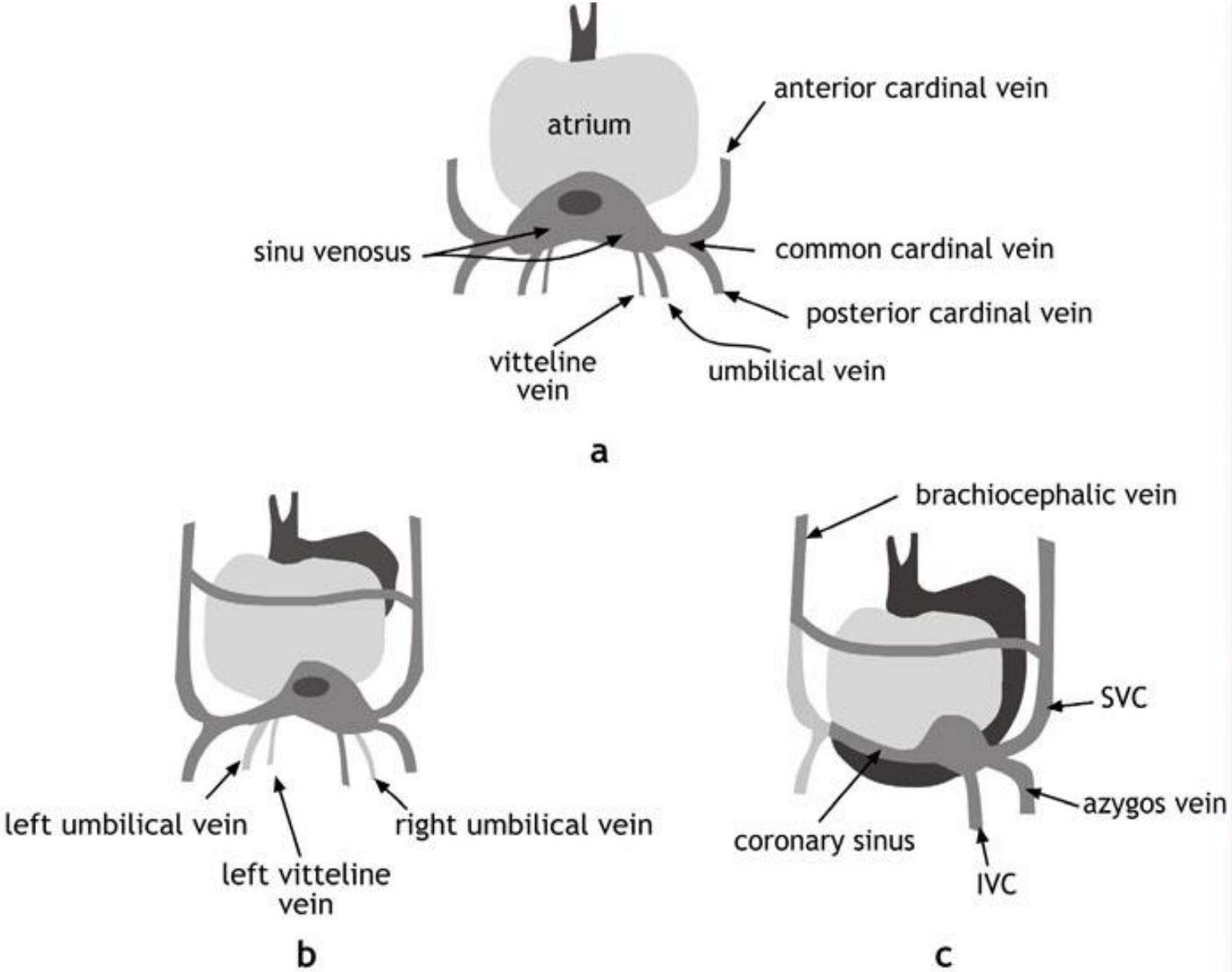
atrium
anterior cardinal vein
sinu venosus
common cardinal vein
posterior cardinal vein
vitteline vein
umbilical vein
a
brachiocephalic vein
SVC
azygos vein
coronary sinus
IVC
left umbilical vein
right umbilical vein
left vitteline vein
b
c

DEVELOPMENT OF THE CARDIAC SEPTA IN COMMON ATRIUM

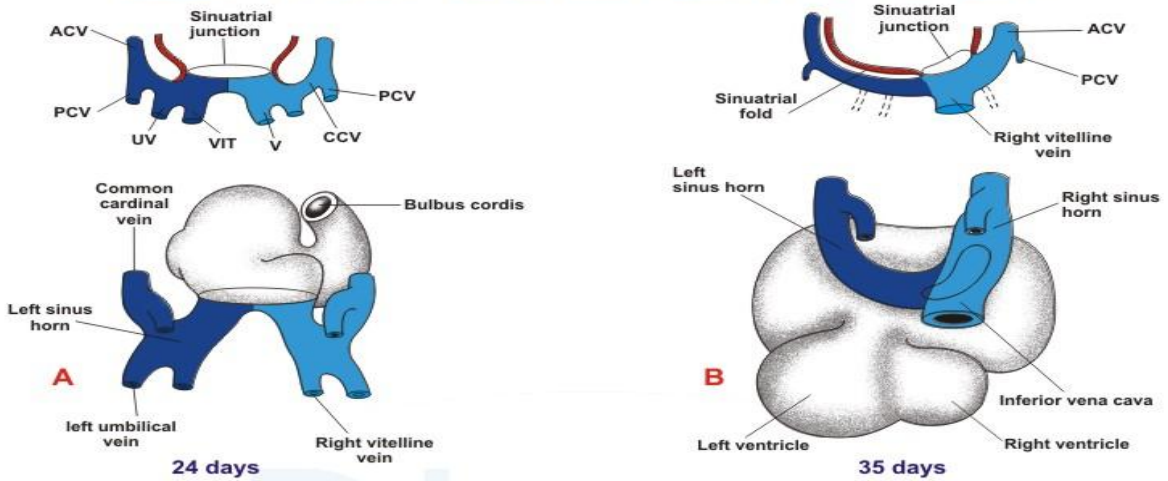

Dorsal view of two stages in the development of the sinus venous at approximately 24 day (A) and 35 days (B) broken line, the entrance of the sinus venosus into the atrial cavity. Each drawing is accompanied by a scheme to show in transverse section the great veins and their relation to the atrial cavity. ACV, anterior cardinal vein; PCV, posterior cardinal vein; UV, umbilical vein; VIT V, vitelline vein; CCV, common cardinal vein.

Final stage in development of the sinus venosus and great veins

Ventral view of coronal sections through the heart at the level of the atrioventricular canal to show development of the venous valves. (A) 5 weeks (B) fetal stage. The sinus venarum (blue) is smooth walled; it derives from the right sinus horn. arrows, blood flow.

CH 2017

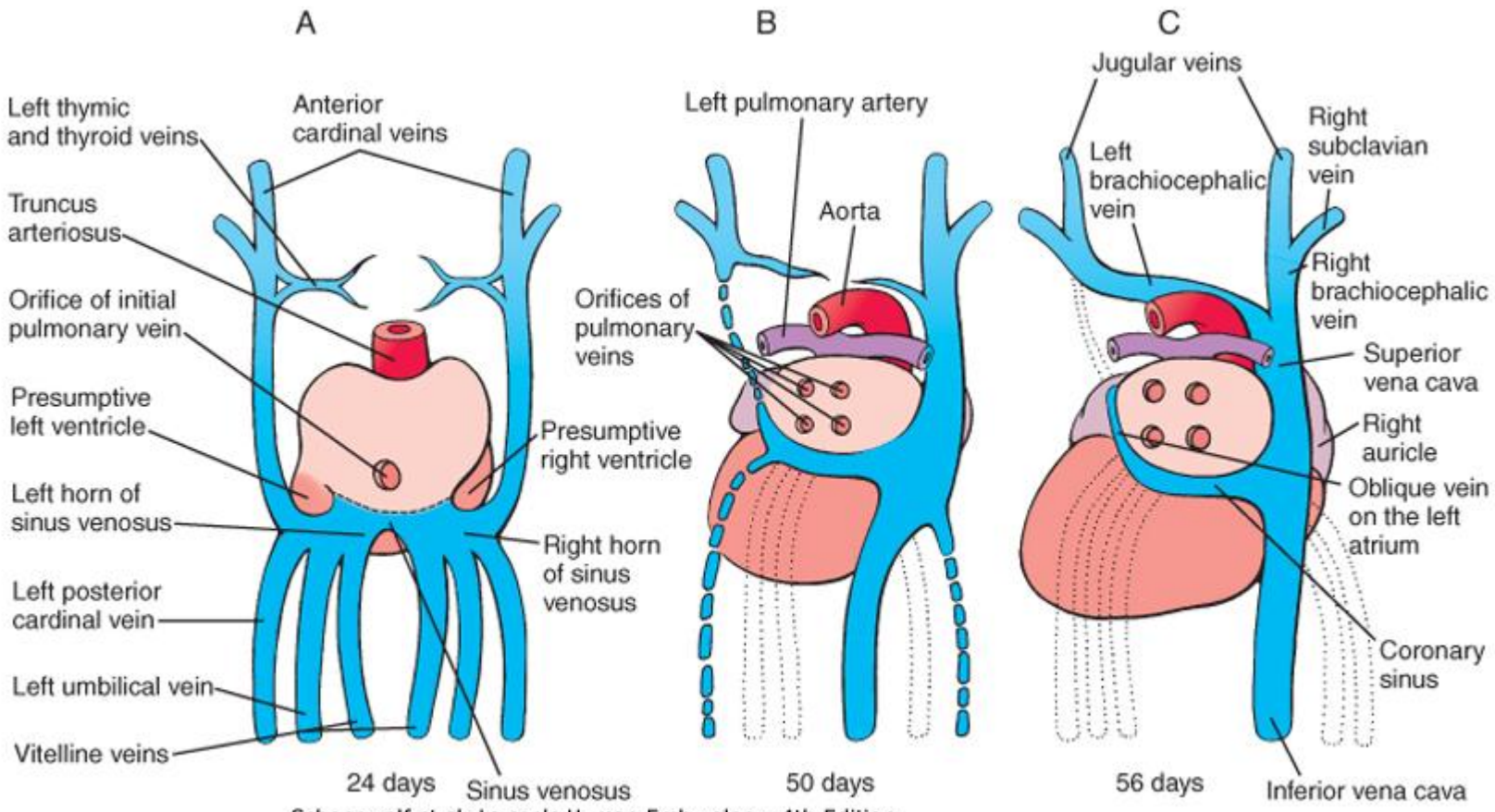

Schoenwolf et al: Larsen's Human Embryology, 4th Edition.
Copyright © 2008 by Churchill Livingstone, an imprint of Elsevier, Inc. All rights reserved

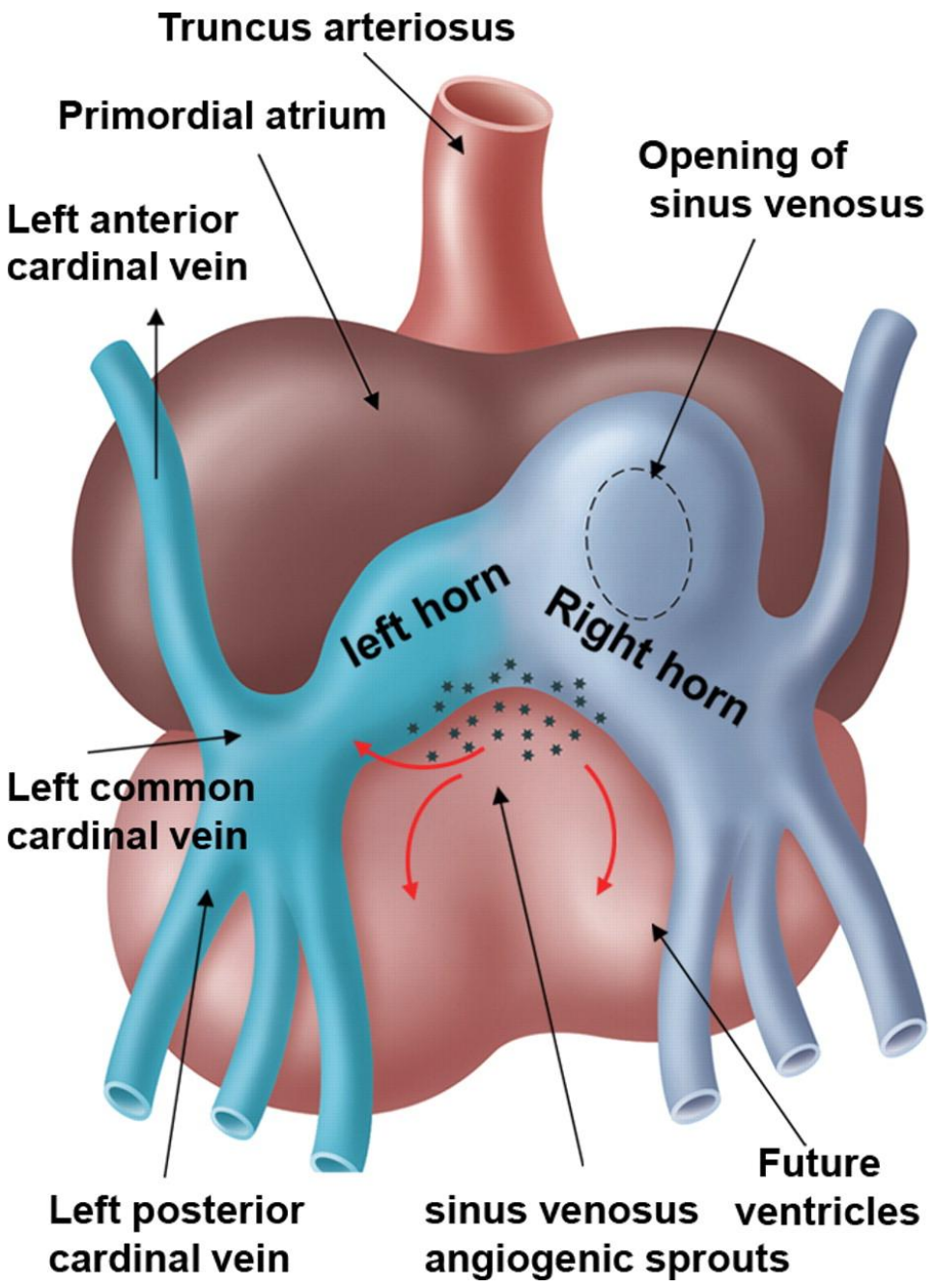
Truncus arteriosus
Primordial atrium
Opening of
sinus venosus
Left anterior
cardinal vein
left horn
Right horn
Left common
cardinal vein
Left posterior
cardinal vein
sinus venosus
angiogenic sprouts
Future
ventricles

Development of Venous Valves

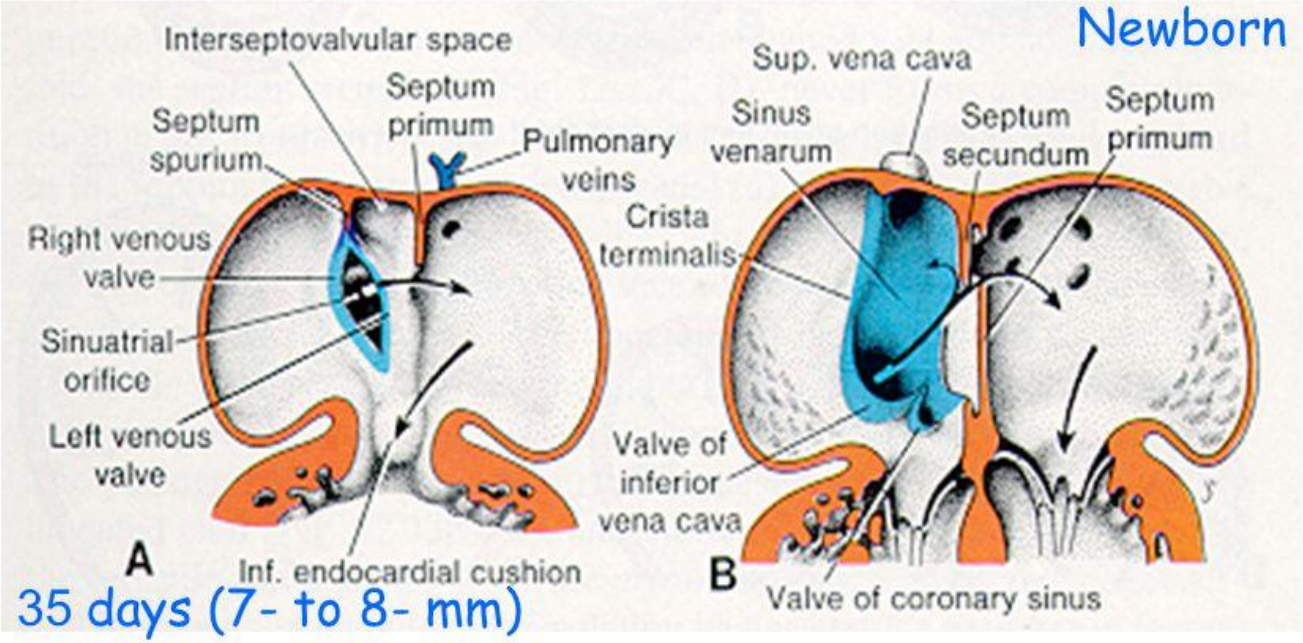

1. Septum spurium = fusion of Rt. & Lt. venous valves.
2. Sup. portion of Rt. venous valve disappears.
3. Inf. portion of Rt. venous valve = valve of IVC & valve of coronary sinus
4. Crista terminalis = dividing line

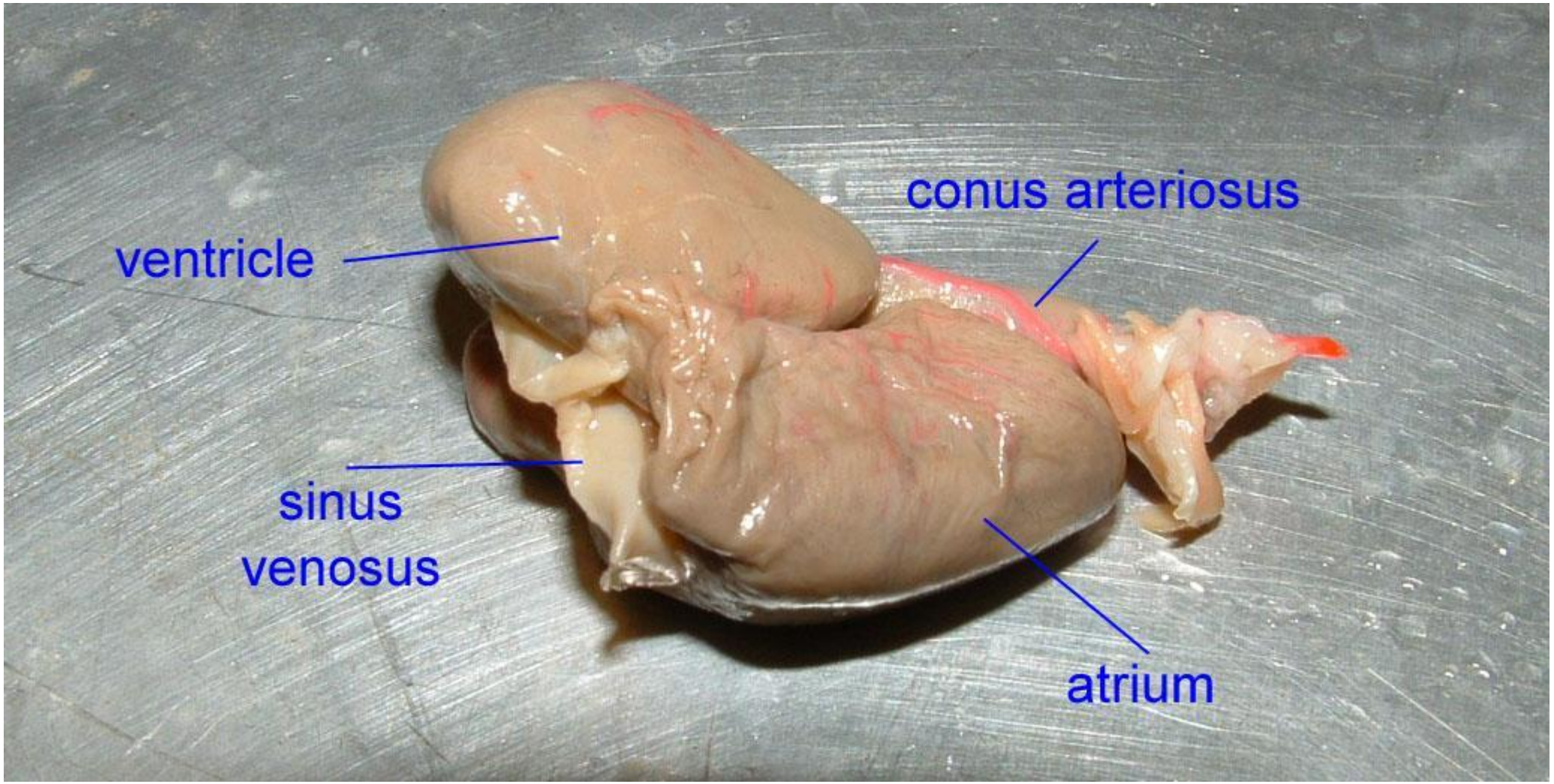
conus arteriosus
ventricle
sinus
venosus
atrium

Formation of left atrium

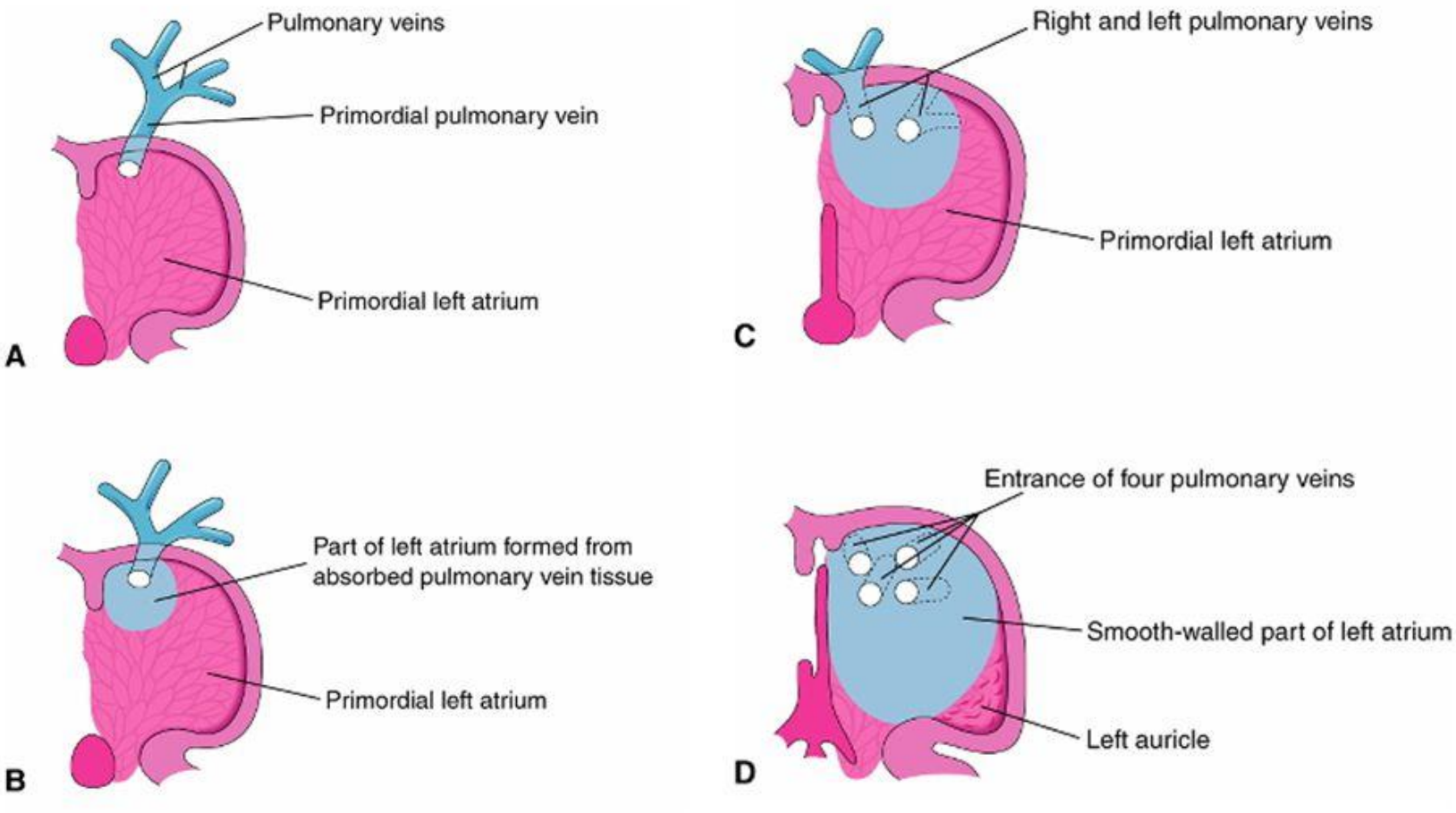

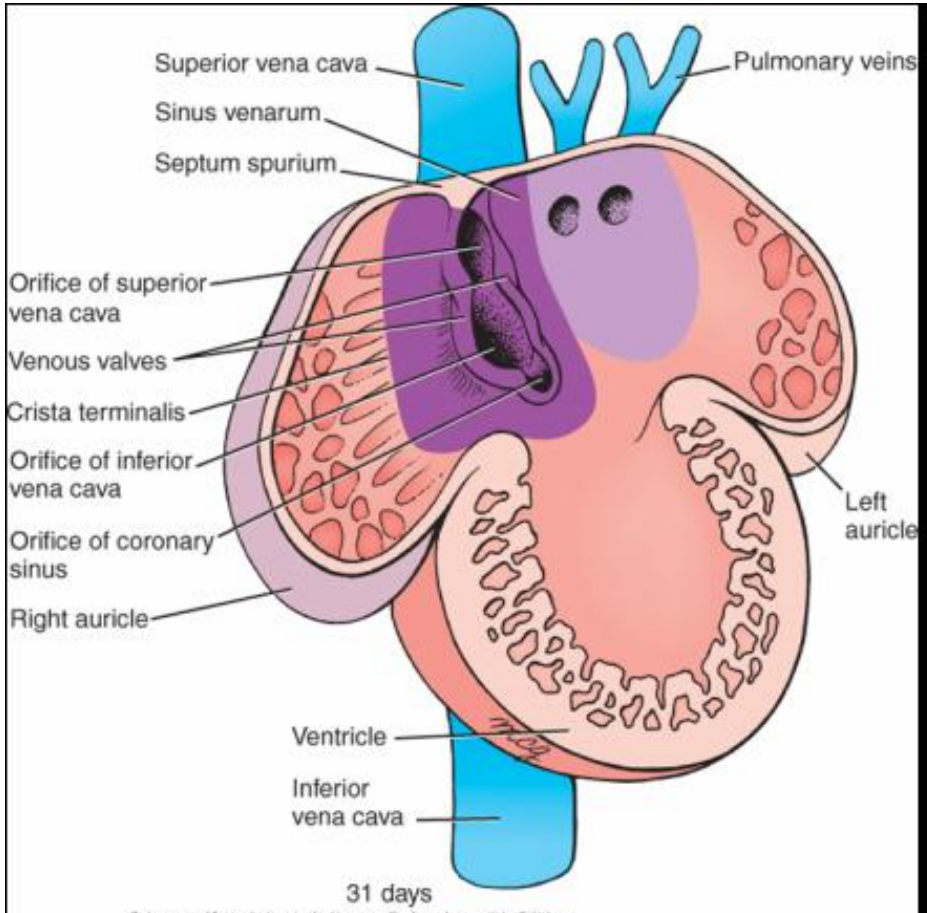

Schoenwolf et al: Larsen's Human Embryology, 4th Edition.
Copyright © 2008 by Churchill Livingstone, an imprint of Elsevier, Inc. All rights reserved

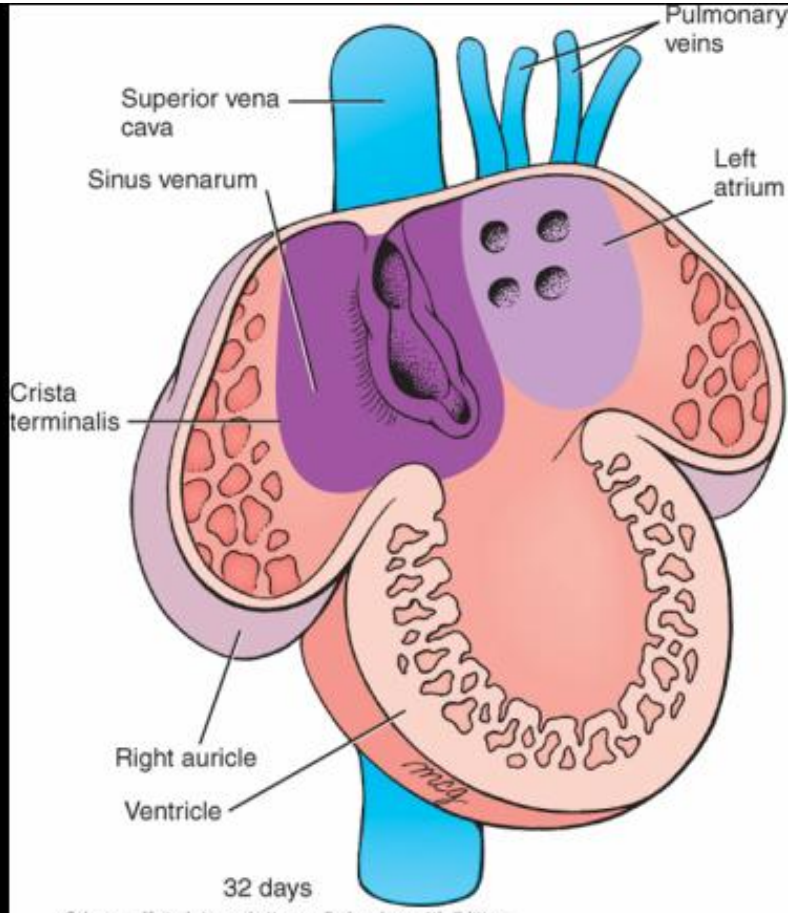

Schoenwolf et al: Larsen's Human Embryology, 4th Edition.
Copyright © 2008 by Churchill Livingstone, an imprint of Elsevier, Inc. All rights reserved

تحجب البطين الابتدائي

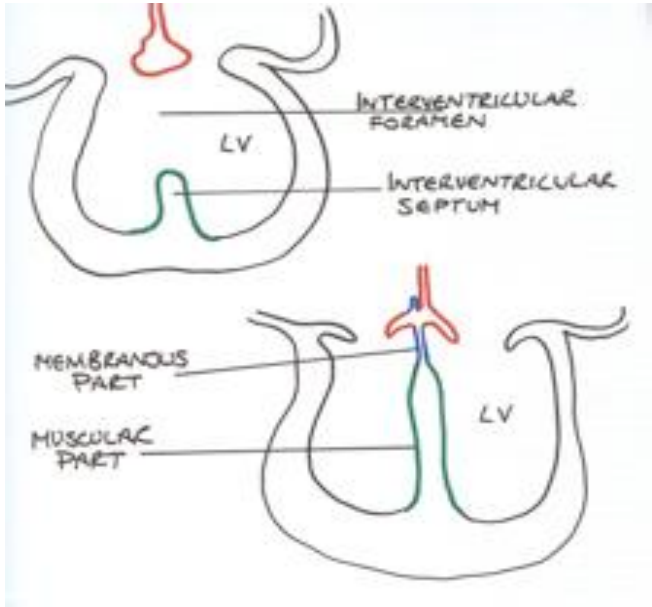

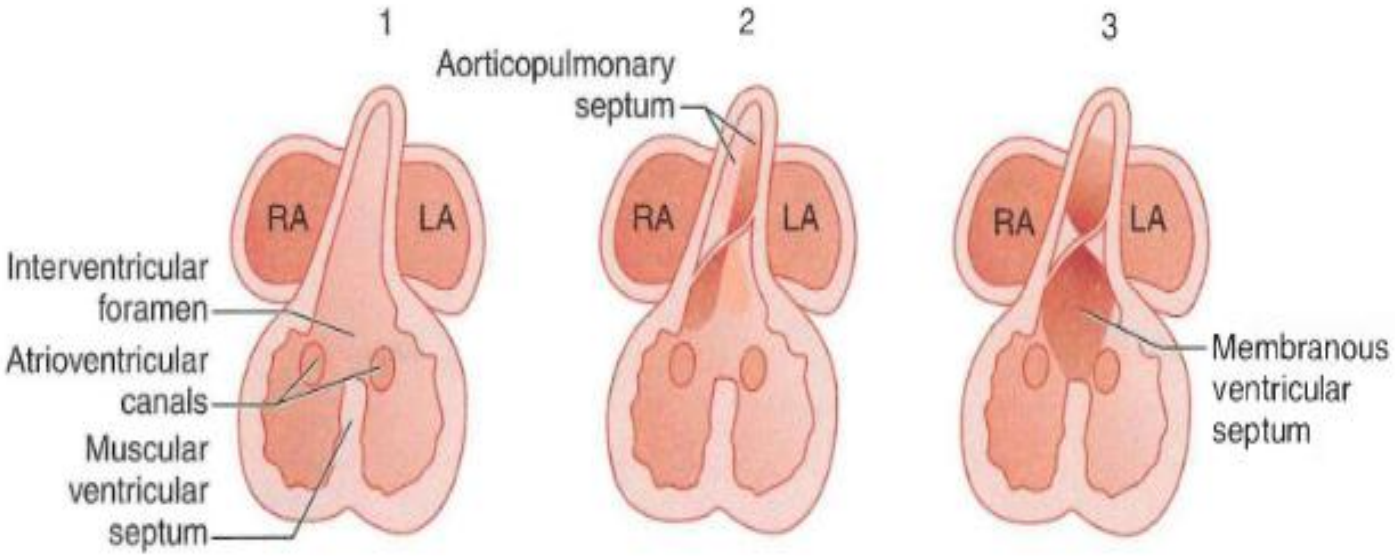

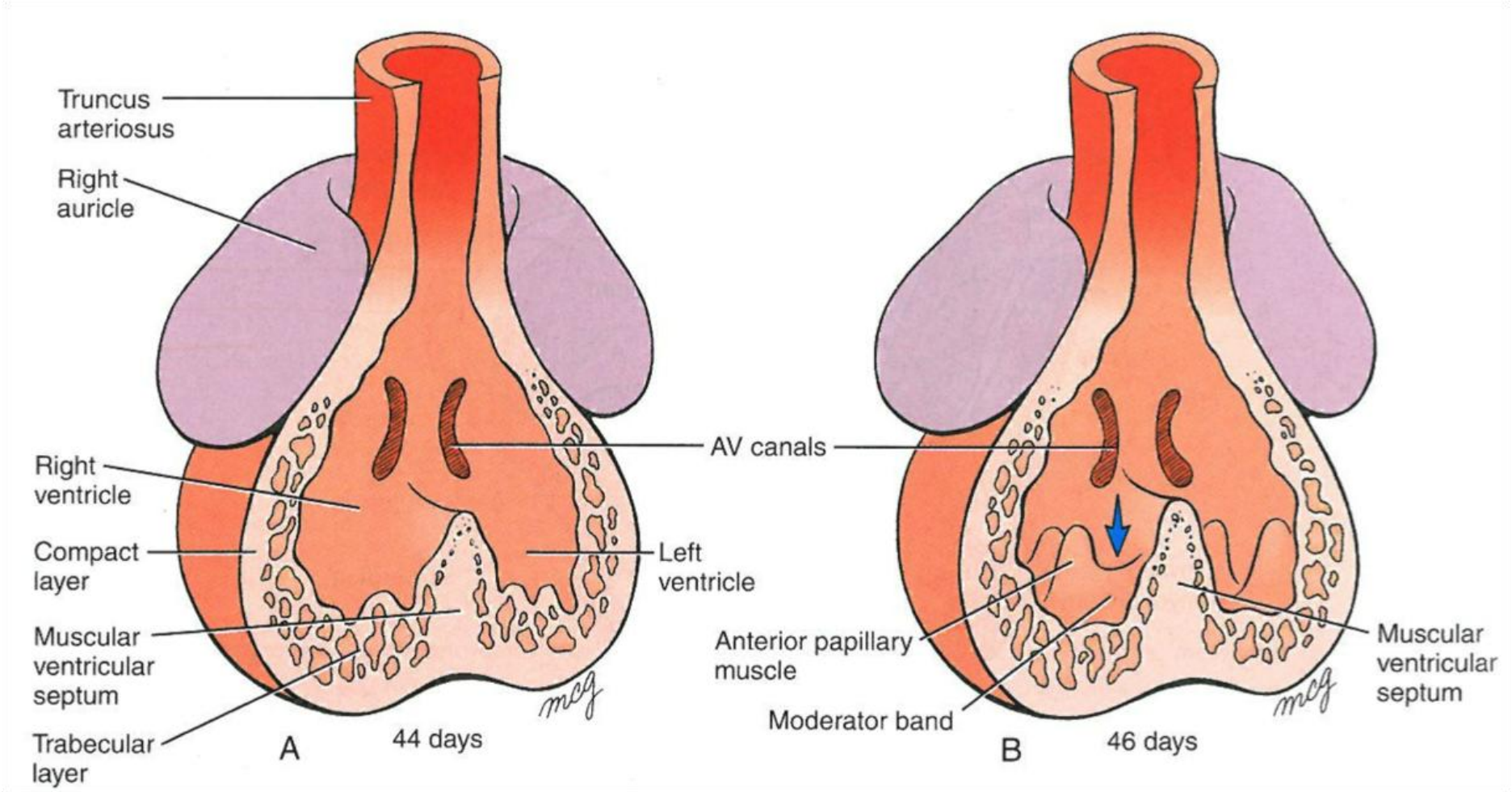
Truncus arteriosus
Right auricle
Right ventricle
Compact layer
Muscular ventricular septum
Trabecular layer
AV canals
Left ventricle
A
44 days
Anterior papillary muscle
Moderator band
Muscular ventricular septum
B
46 days

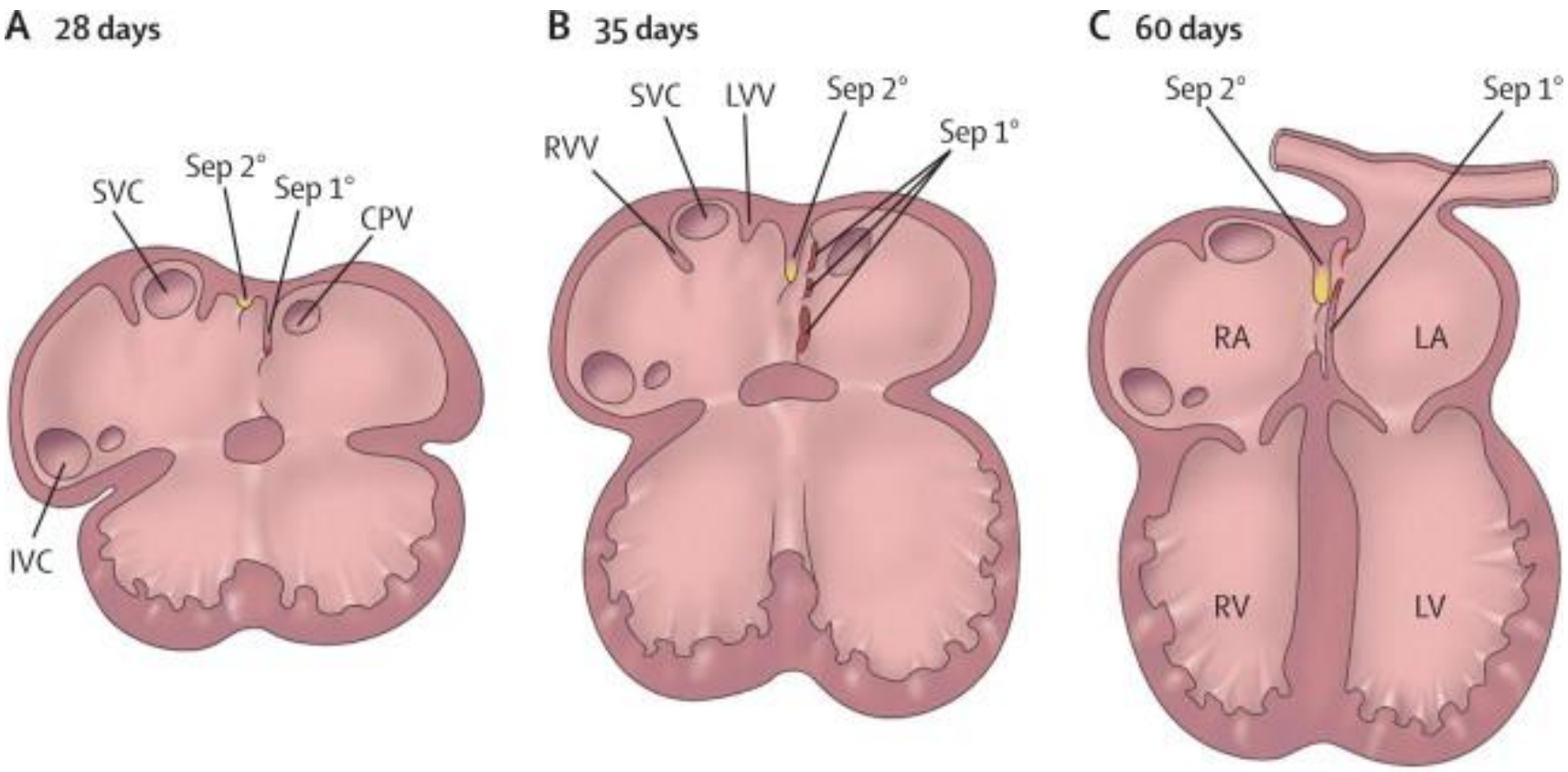
A 28 days
SVC
Sep 2°
Sep 1°
CPV
IVC
B 35 days
RVV
SVC
LVV
Sep 2°
Sep 1°
C 60 days
Sep 2°
Sep 1°
RA
LA
RV
LV

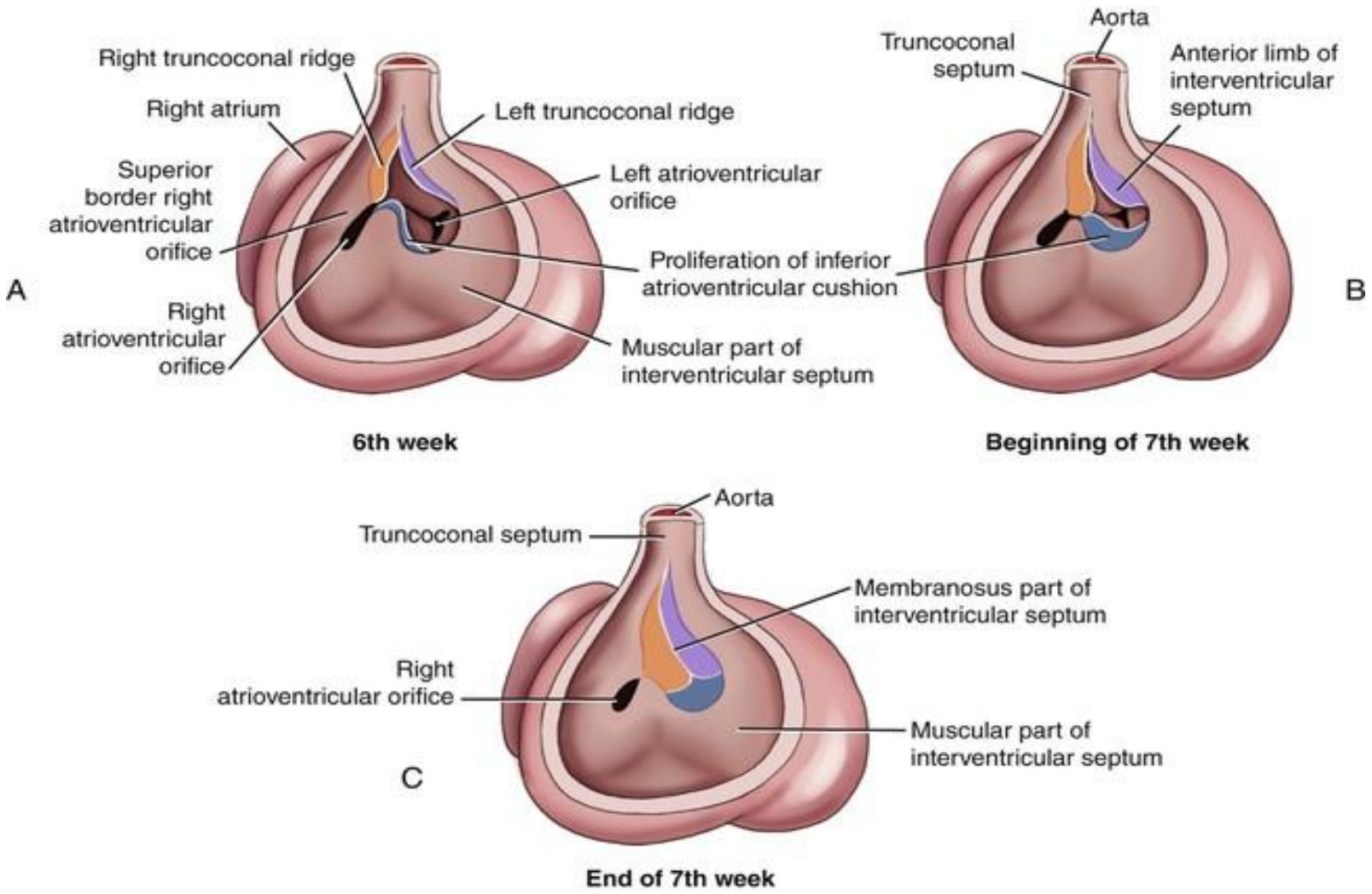
Right truncoconal ridge
Right atrium
Left truncoconal ridge
Superior border right atrioventricular orifice
Left atrioventricular orifice
Proliferation of inferior atrioventricular cushion
A
Right atrioventricular orifice
Muscular part of interventricular septum
6th week
Aorta
Truncoconal septum
Anterior limb of interventricular septum
B
Beginning of 7th week
Aorta
Truncoconal septum
Membranosus part of interventricular septum
Right atrioventricular orifice
Muscular part of interventricular septum
C
End of 7th week

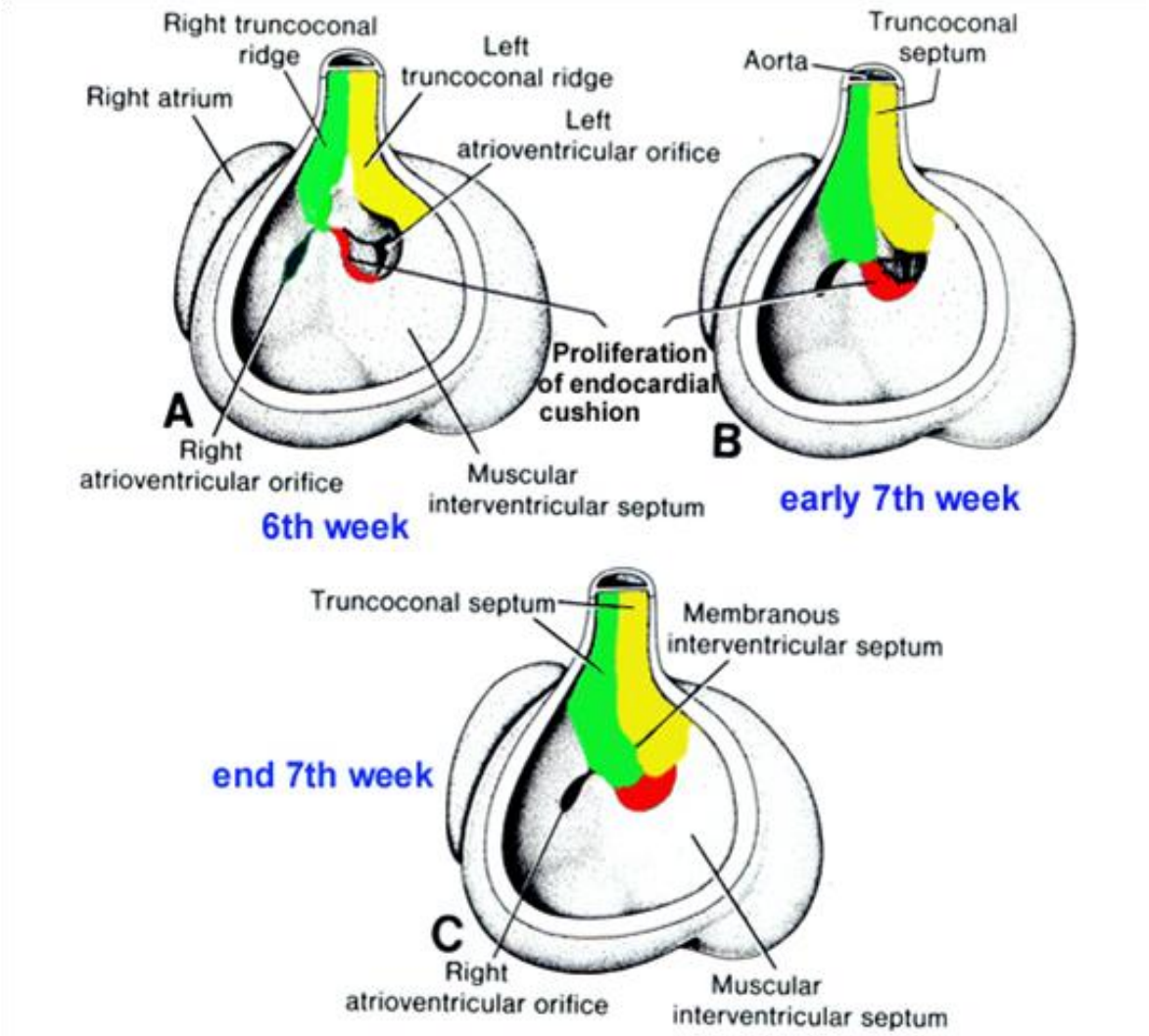
Right truncoconal ridge
Left truncoconal ridge
Right atrium
Left atrioventricular orifice
Proliferation of endocardial cushion
A
Right atrioventricular orifice
Muscular interventricular septum
6th week
Truncoconal septum
Aorta
B
early 7th week
Truncoconal septum
Membranous interventricular septum
end 7th week
C
Right atrioventricular orifice
Muscular interventricular septum

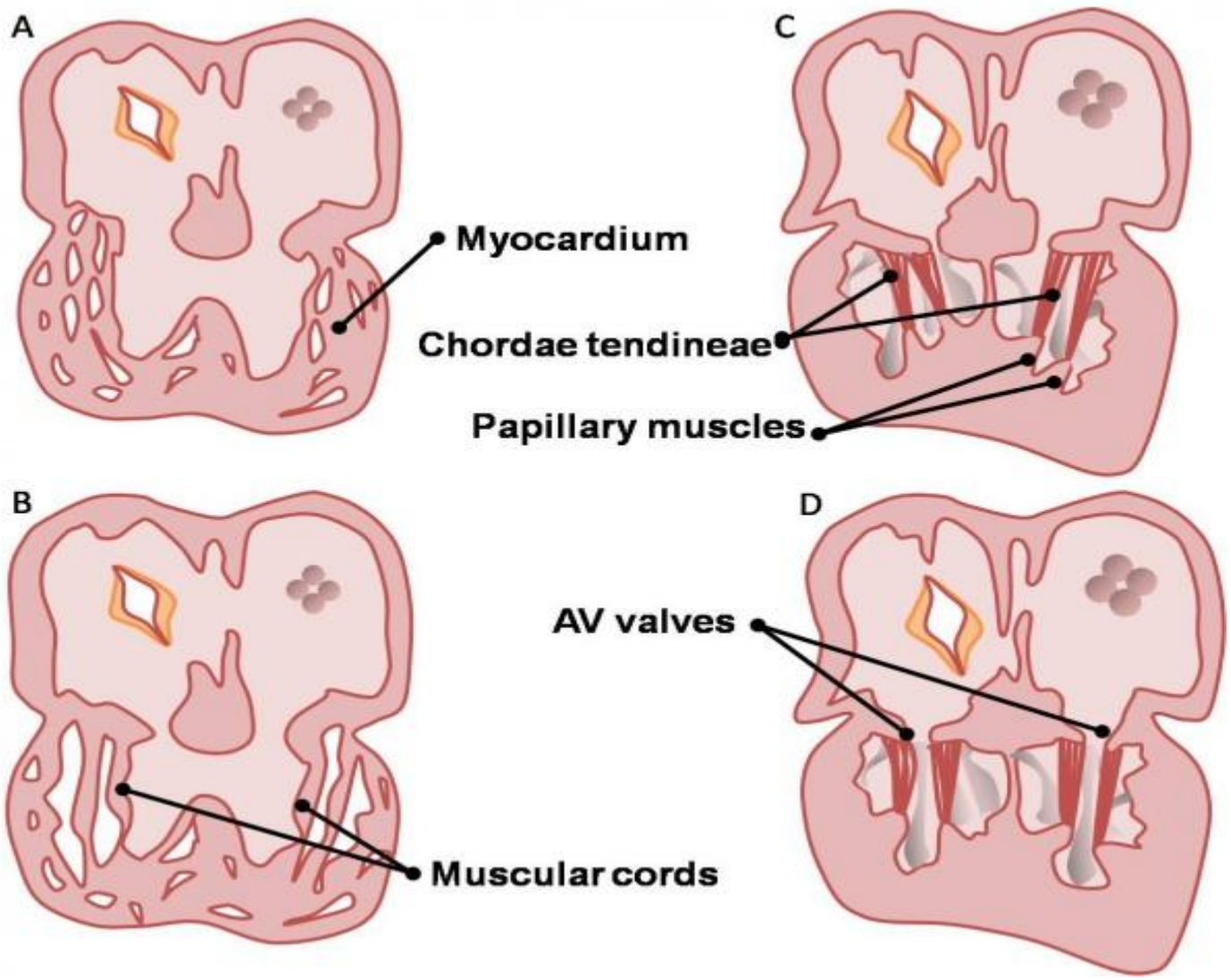
A
Myocardium
C
Chordae tendineae
Papillary muscles
B
Muscular cords
D
AV valves

تقسيم البصلة الشريانية والجذع الشرياني ومصيرهما

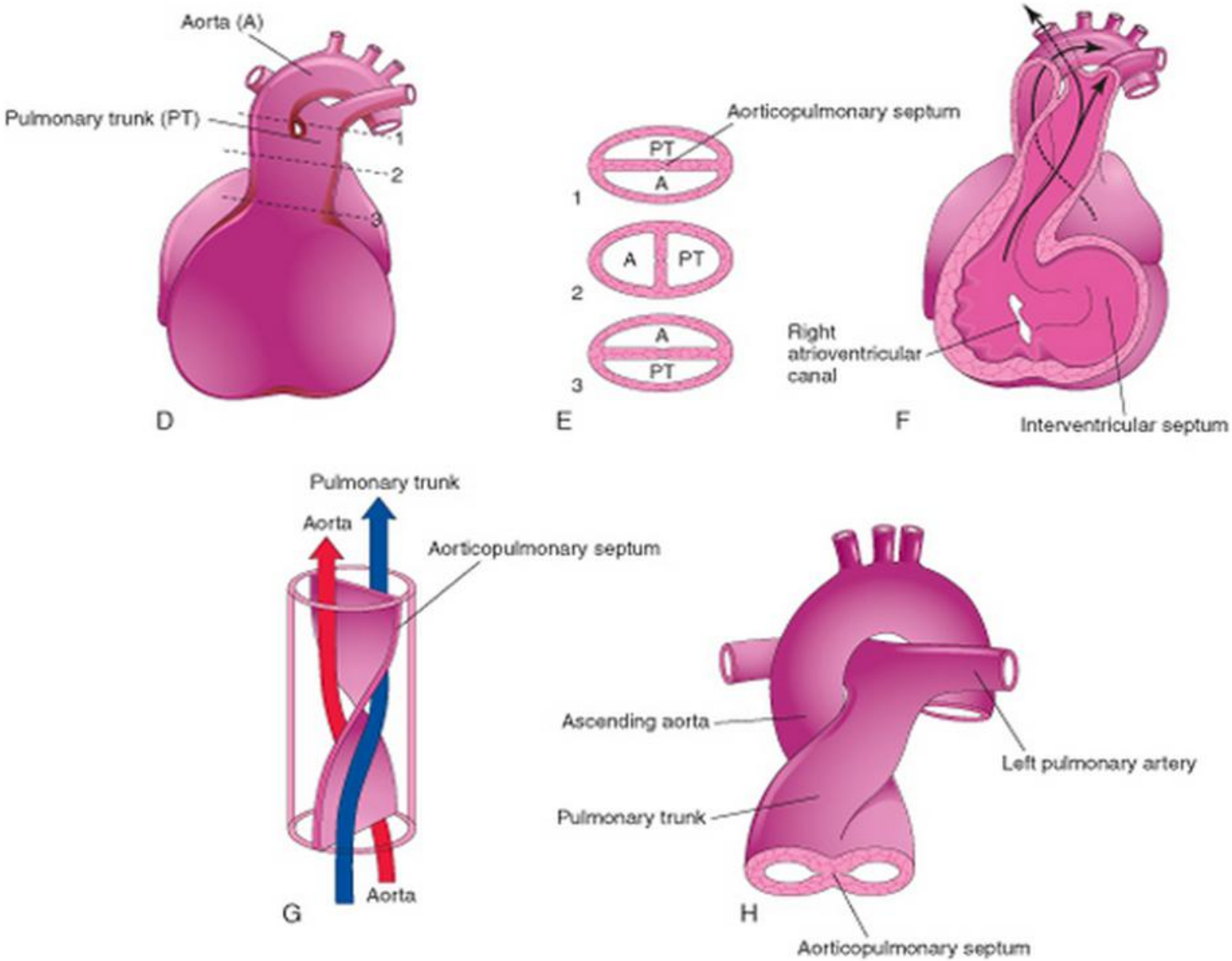

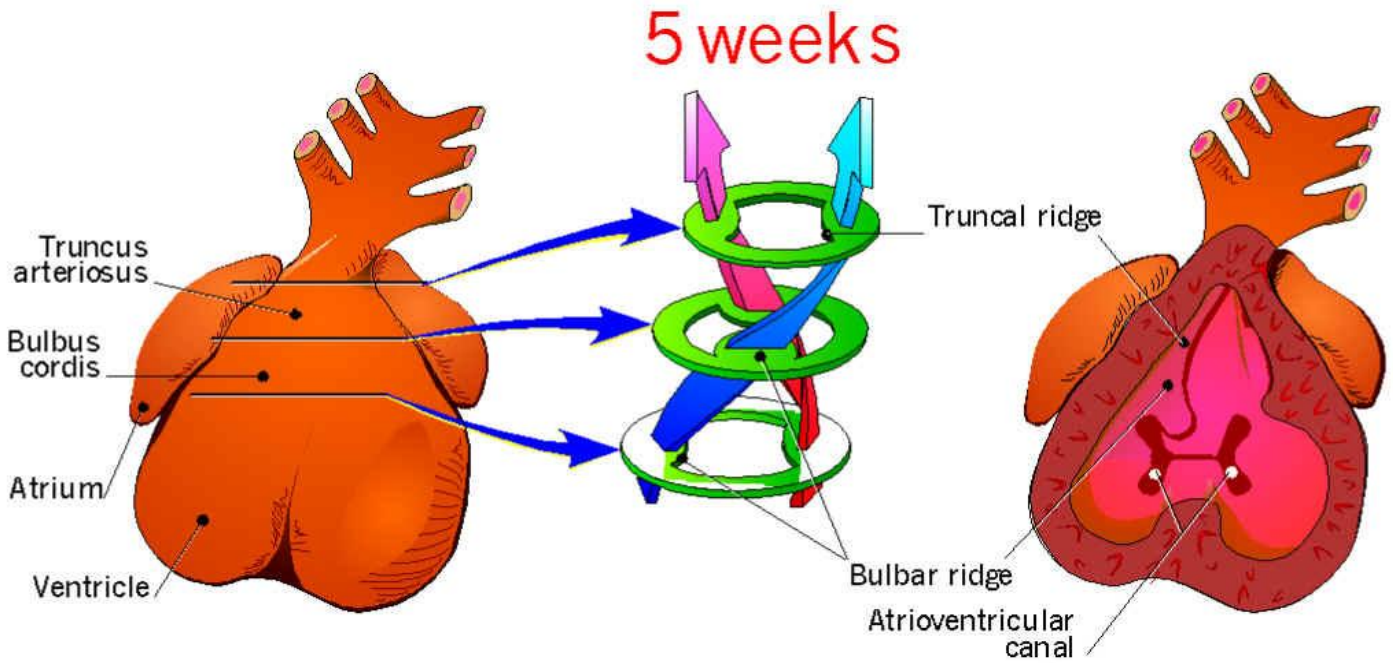
5 weeks
Truncus arteriosus
Bulbus cordis
Atrium
Ventricle
Truncal ridge
Bulbar ridge
Atrioventricular canal

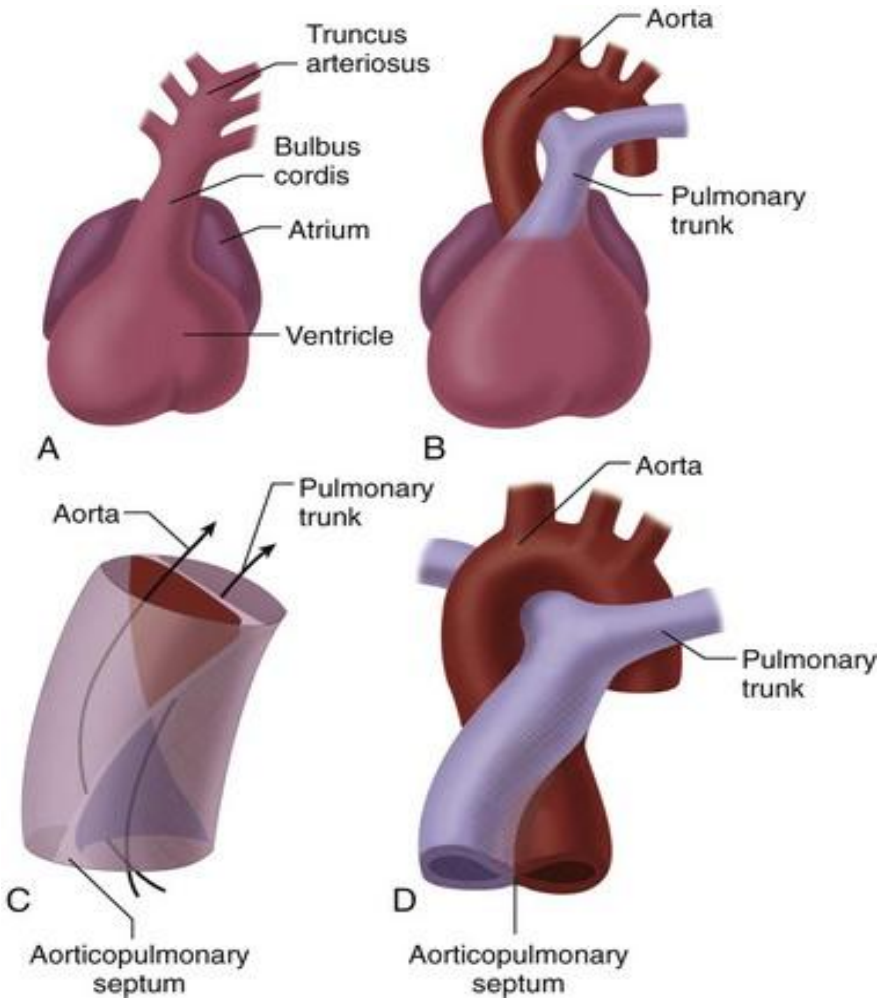
Truncus arteriosus
Bulbus cordis
Atrium
Ventricle
A
Aorta
Pulmonary trunk
B
Aorta
Pulmonary trunk
C
Aorticopulmonary septum
Aorta
Pulmonary trunk
D
Aorticopulmonary septum

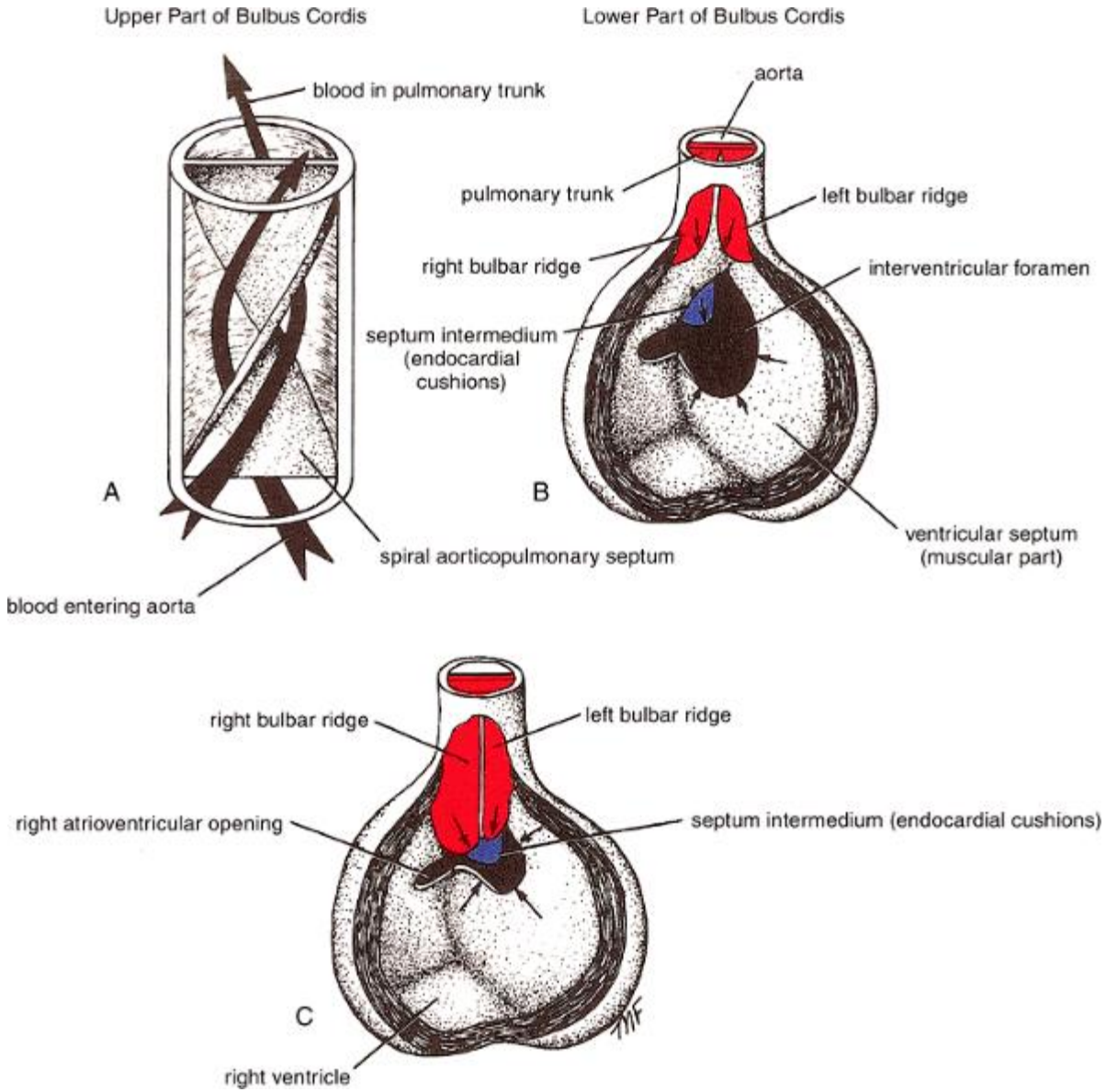
Upper Part of Bulbus Cordis
Lower Part of Bulbus Cordis
blood in pulmonary trunk
aorta
pulmonary trunk
left bulbar ridge
right bulbar ridge
interventricular foramen
septum intermedium
(endocardial
cushions)
A
B
spiral aorticopulmonary septum
ventricular septum
(muscular part)
blood entering aorta
right bulbar ridge
left bulbar ridge
right atrioventricular opening
septum intermedium (endocardial cushions)
C
right ventricle

Developments of the Cardiac Valves

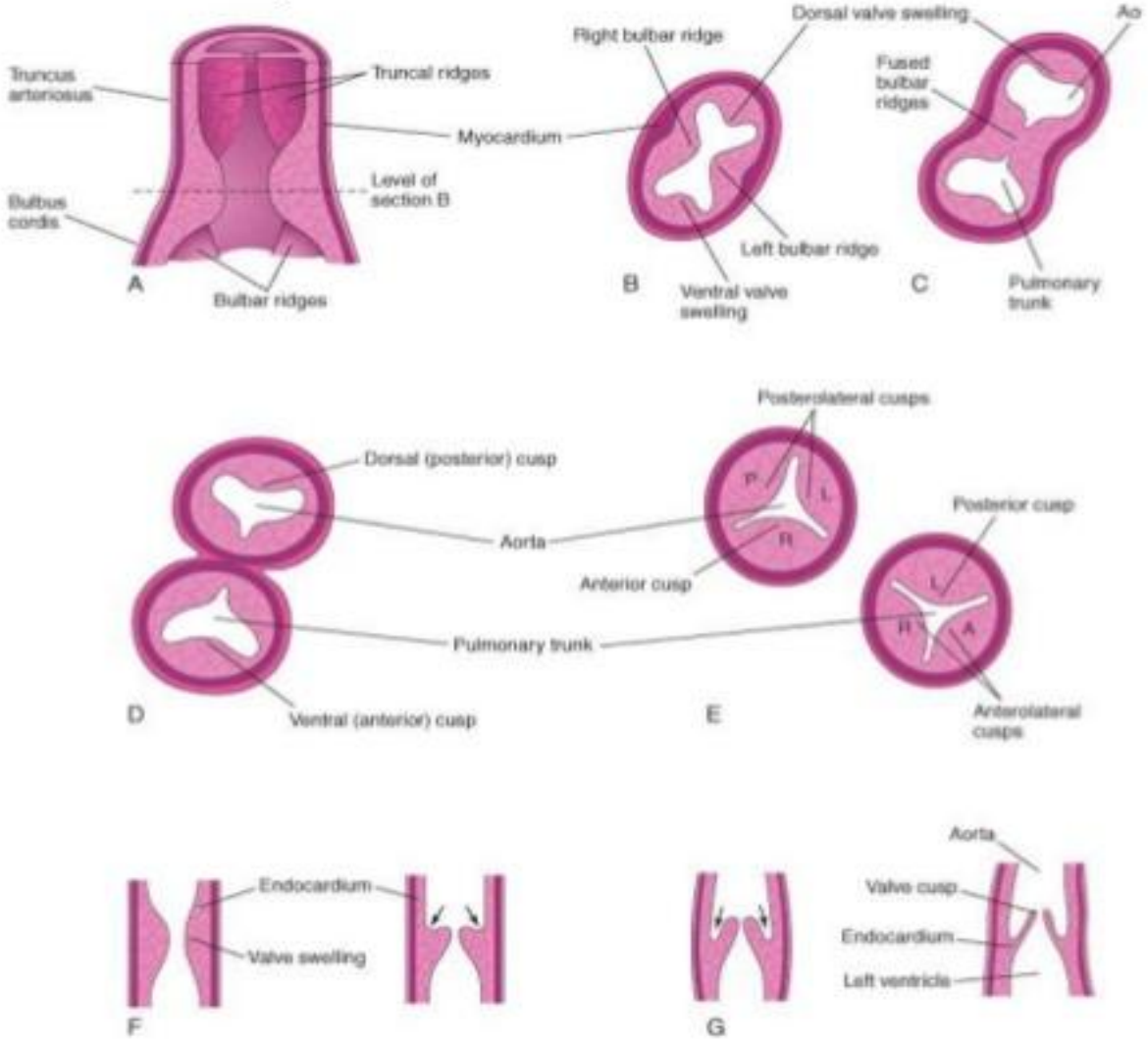

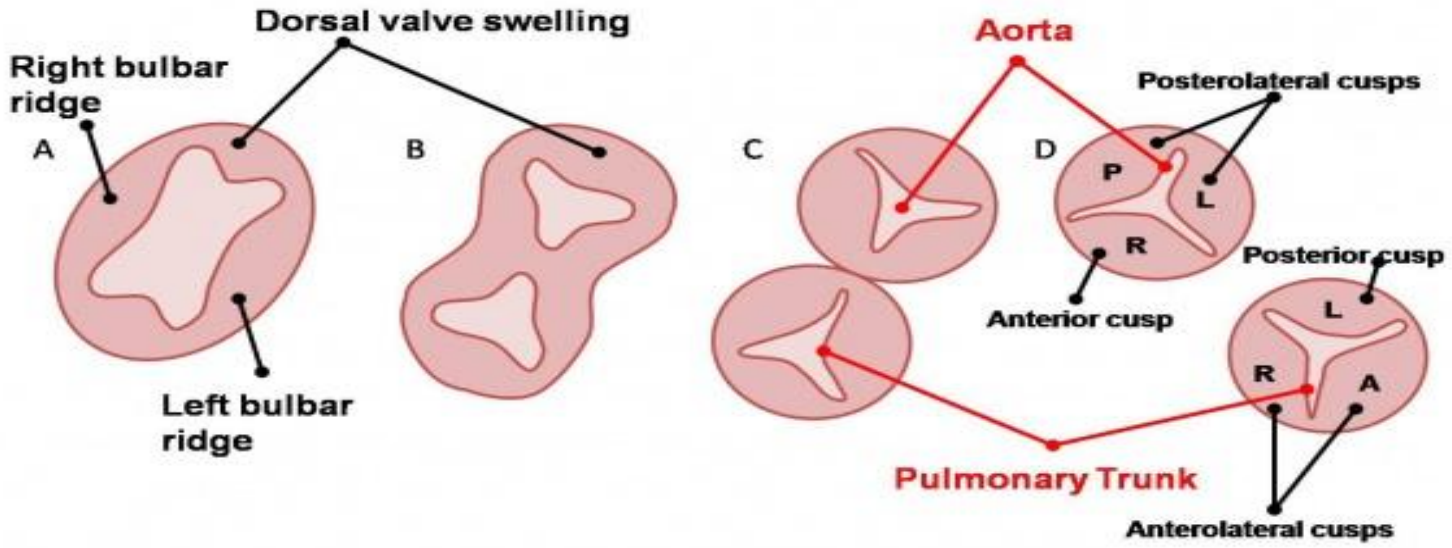
Dorsal valve swelling
Right bulbar ridge
A
B
Left bulbar ridge
Aorta
Posterolateral cusps
C
D
P
L
R
Anterior cusp
Posterior cusp
L
R
A
Pulmonary Trunk
Anterolateral cusps

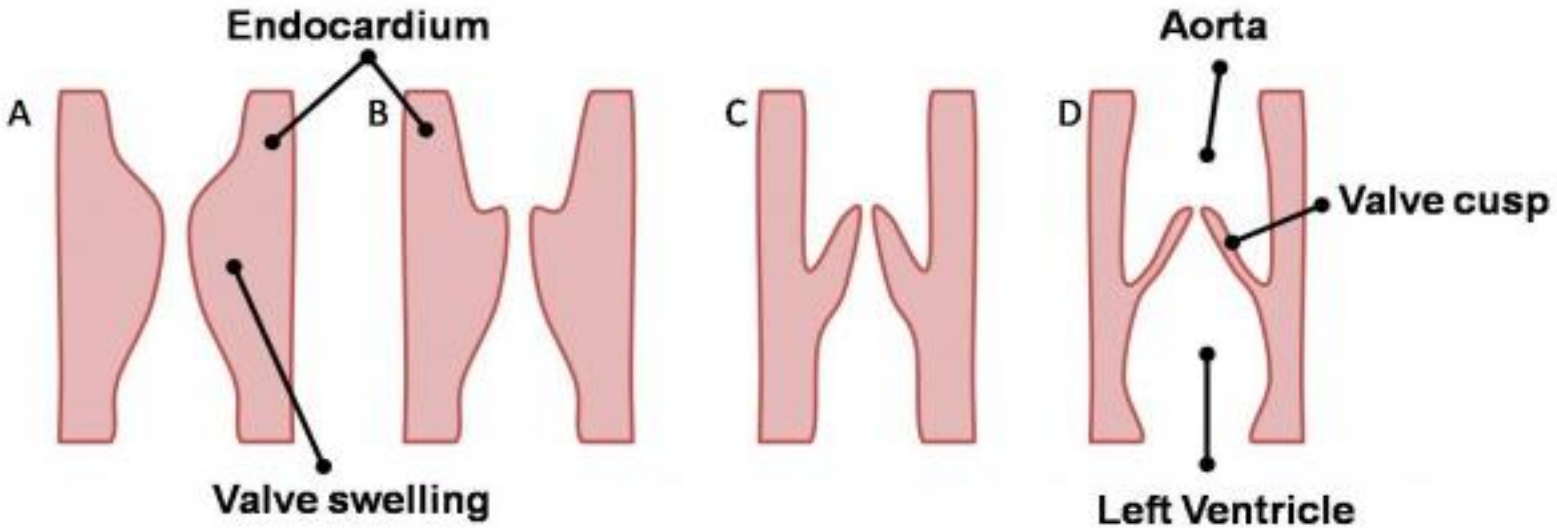
Endocardium
A
B
C
D
Aorta
Valve cusp
Valve swelling
Left Ventricle

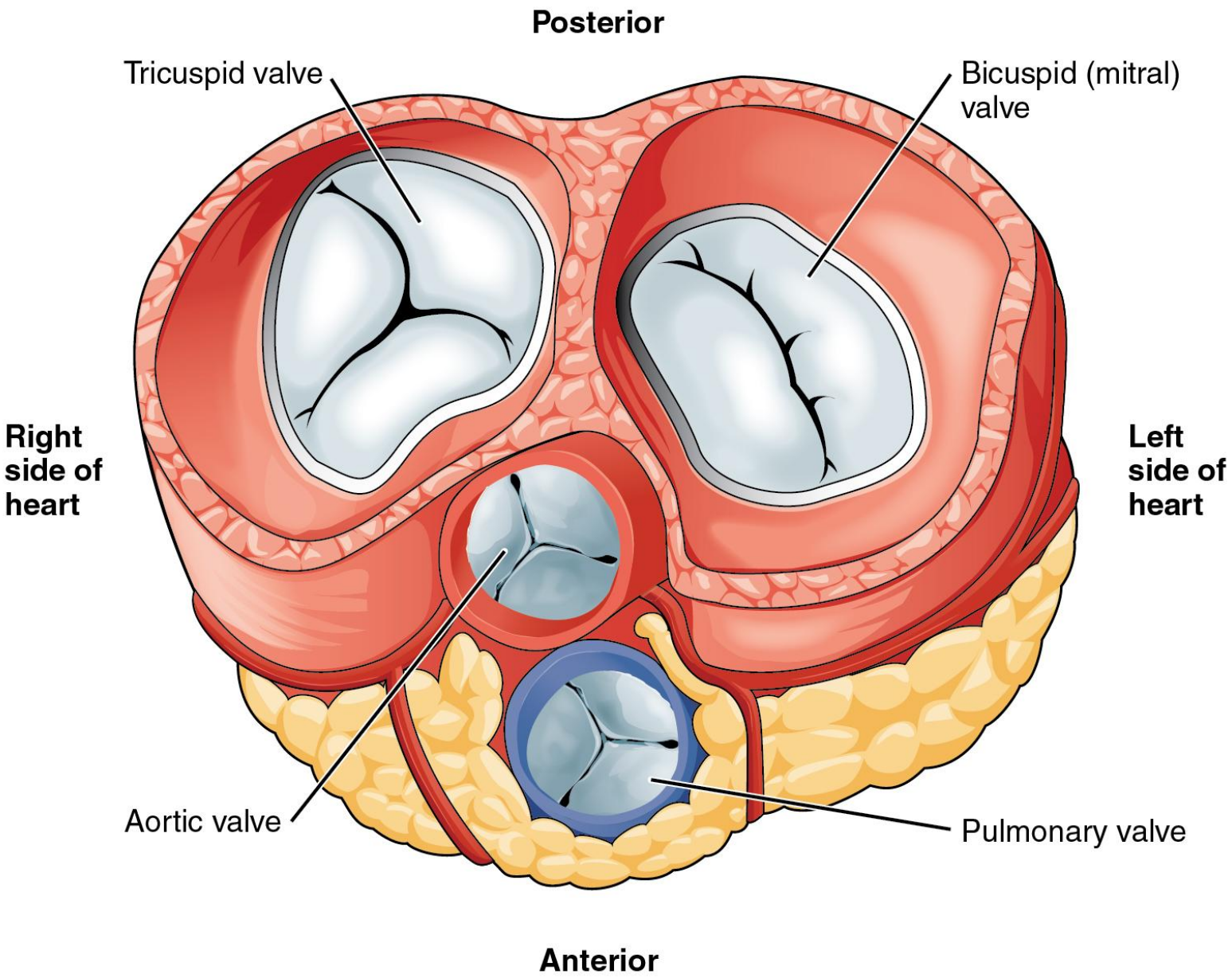
Posterior
Tricuspid valve
Bicuspid (mitral) valve
Right side of heart
Left side of heart
Aortic valve
Pulmonary valve
Anterior

Formation of Cardiac valves

2. Mitral valves & Tricuspid valves (Atrioventricular Valves)

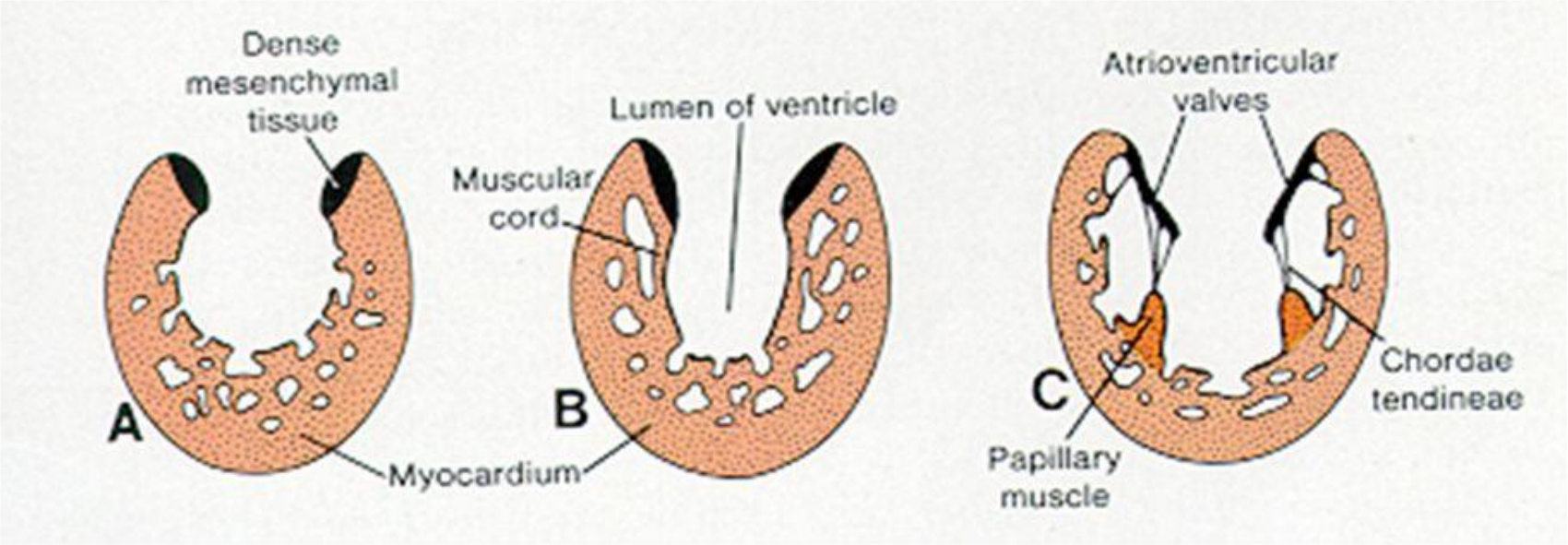

1. Proliferation of mesenchyme in A-V orifice.
2. The cords becomes hollowed out by bloodstream.
3. The muscular tissue degenerates, replaced by dense CNT.
4. A-V valves = CNT covered by endocardium connected to papillary muscles by chordae tendineae.
5. Right = tricuspid valves Left = bicuspid (Mitral) valves

Formation of semilunar valves

also outflow cushion dependent…

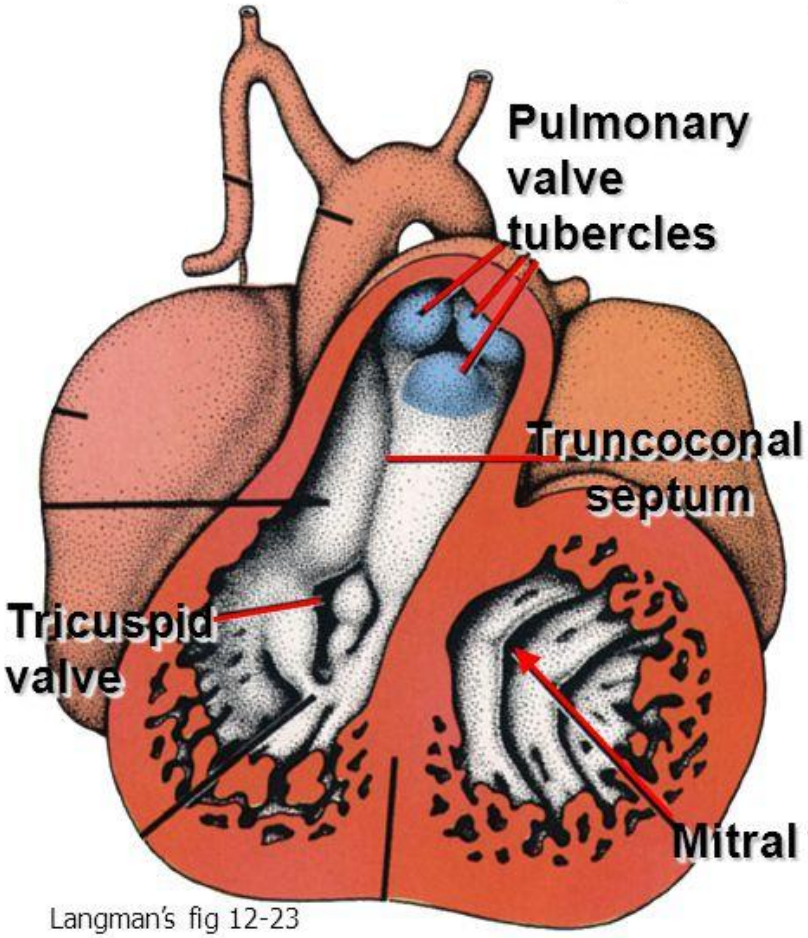

Langman's fig 12-23

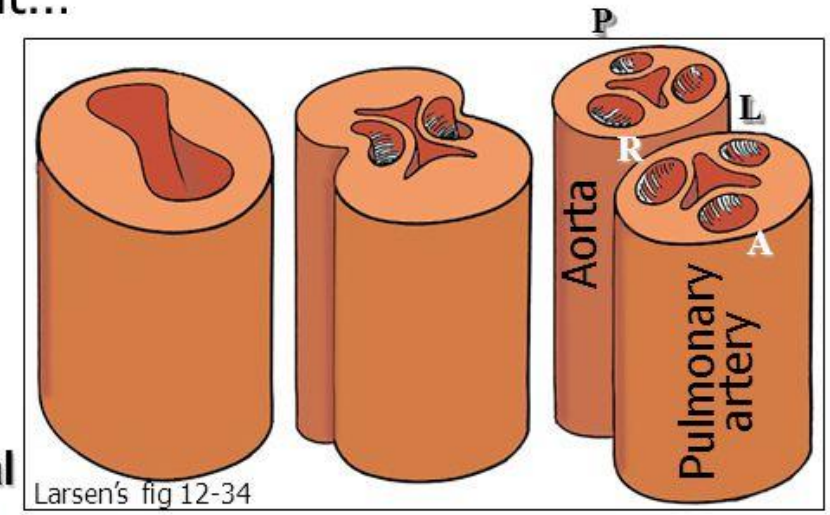

Larsen's fig 12-34

Langman's fig 12-27

1 Aorta
2 Conotruncal crease
3 Truncus pulmonalis
4 Posterior aortic valve
5 Left aortic valve
6 Right aortic valve
7 Right truncus pulmonalis valve
8 Anterior truncus pulmonalis valve
9 Left truncus pulmonalis valve

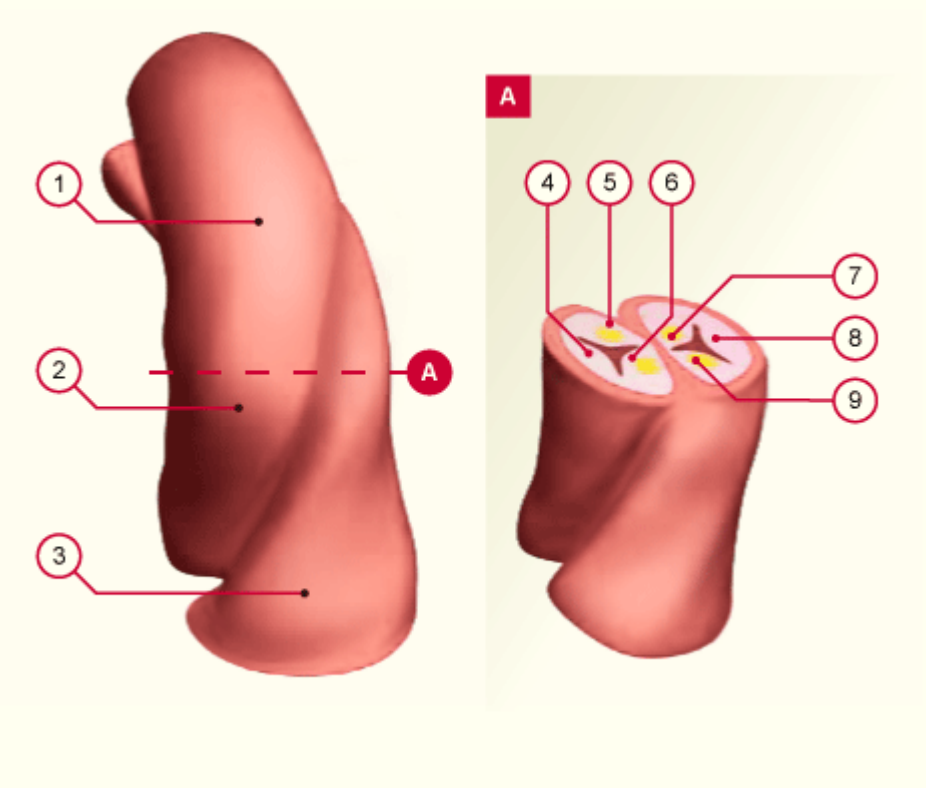

"Embryology Of The Heart"

Middle Of 3rd Week

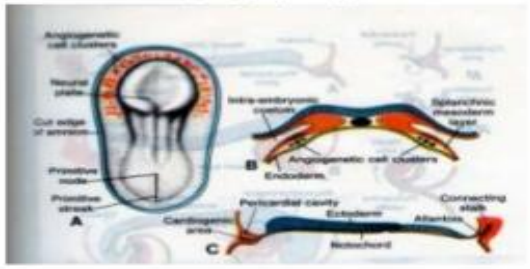

Rotation Of Cardiogenic Area

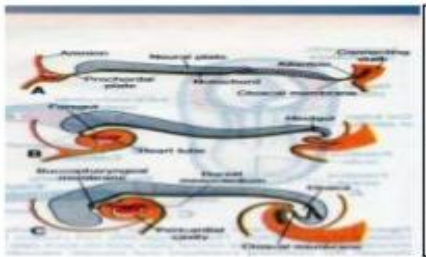

18 Days

21 Days

22 Days

Fusion Of The Heart Tubes

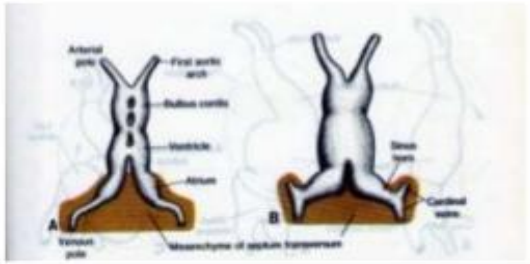

Myoepicardial Mantle

1.Myoblast

2.Mesothelial Cells

The formation of Cardiac Loop

("bending of the heart")

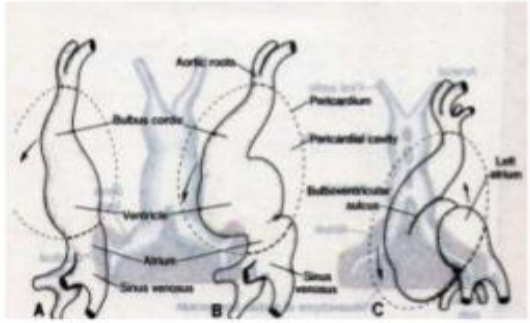

The formation of Cardiac Loop

("bending of the heart at 28th day)

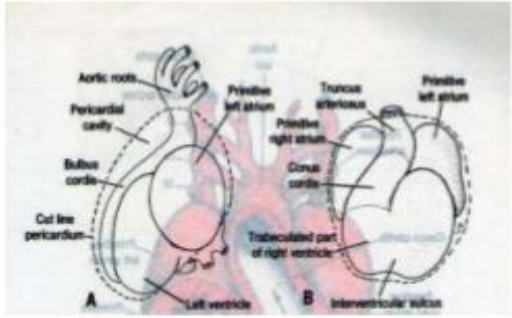

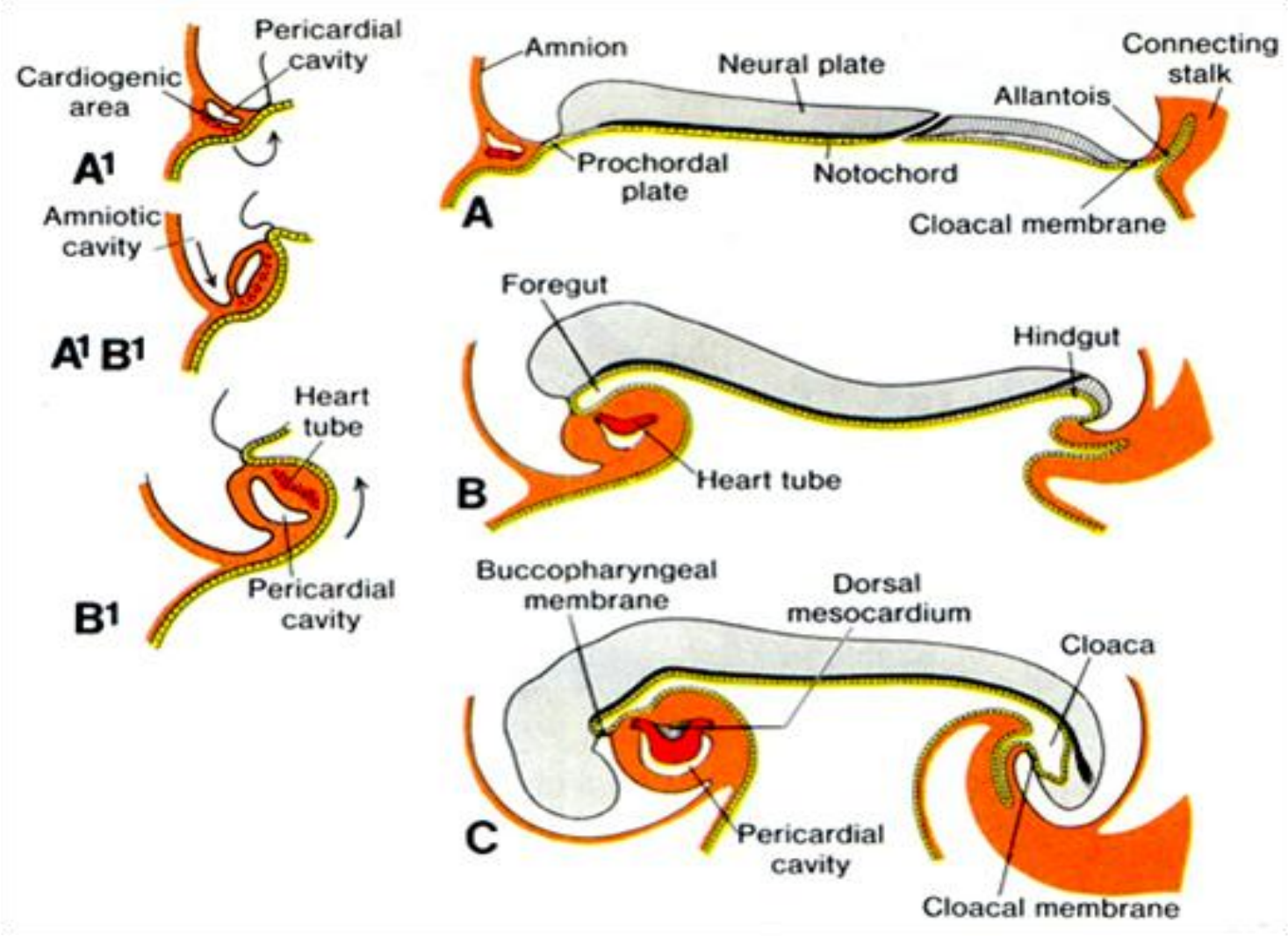
Pericardial cavity
Cardiogenic area
A1
Amniotic cavity
A1 B1
Heart tube
Pericardial cavity
B1
Amnion
Neural plate
Connecting stalk
Allantois
Prochordal plate
Notochord
A
Cloacal membrane
Foregut
Hindgut
Heart tube
B
Buccopharyngeal membrane
Dorsal mesocardium
Cloaca
C
Pericardial cavity
Cloacal membrane